

Case report**PECTORO-EPICONDYLARIS: A RARE EXTENSION OF THE PECTORALIS MAJOR MUSCLE****Sushma R. Kotian, Kumar M. R. Bhat***Department of Anatomy, Kasturba Medical College, Manipal University, Manipal, India***RESUMEN**

El músculo pectoral mayor es propenso a varias incongruencias morfológicas. Diferentes deslizamientos musculares son comunes entre ellos. Sin embargo, durante la disección rutinaria de un cadáver masculino de 55 años por estudiantes de pregrado, se encontró una variante rara de la extensión tendinosa del músculo pectoral mayor. Surgía de la lámina profunda del tendón muscular bilaminar cerca de su inserción en el húmero. En su camino a unirse al tabique intermuscular medial del brazo y finalmente al epicóndilo medial del húmero, cruzó todas las estructuras en la parte delantera del brazo de lateral a medial. Considerando la extensión tendinosa de forma proximal, no se observó formación muscular separada. Esta variante de deslizamiento puede ser nombrada como músculo pectoral epicondilar. El conocimiento de esta variación particular puede ser de especial interés para los radiólogos y médicos en procedimientos tales como transformación de músculo, trasplante de tendón y uso en los colgajos miocutáneos durante cirugías reconstructivas.

Palabras clave: *Pectoral mayor, pectoro-epicondylaris, septo intermuscular medial, epicóndilo medial.*

ABSTRACT

The pectoralis major muscle is prone to various morphological incongruities. Variant muscular slips are common among them. However during routine dissection for undergraduate students in a 55-year-old male cadaver, a rare variation of the tendinous extension of the pectoralis major muscle was found. It was arising from the deep lamina of the muscular bilaminar tendon close to its insertion to the humerus. On its way to be attached to the medial intermuscular septum of the arm and finally to the medial epicondyle of the humerus, it crossed all the structures in the front of the arm from lateral to medial. Tracing this tendinous extension slip proximally, no separate muscular

extension was observed. This variant slip may be named as pectoro-epicondylaris muscle. The knowledge of this particular variation could be of special interest to radiologists and clinicians in procedures such as muscle transformation, tendon transplantation and use of myo-cutaneous flaps during reconstructive surgeries.

Key Words : *Pectoralis major, pectoro-epicondylaris, medial intermuscular septum, medial epicondyle*

INTRODUCTION

The pectoralis major muscle normally arises from the clavicle, sternum, 2nd to 6th ribs and respective costal cartilages and the aponeurosis of the external oblique muscle of the abdomen and is inserted to the lateral lip of the intertubercular sulcus of the humerus. However variations in the attachments of the muscle have been reported (Standerling, 2005). Earlier it has been stated that the pectoralis major may have extensions such as chondro-fascialis, chondro-epitrochlearis, thoraco-epitrochlearis, arising from the chest wall and attaching either directly on to the humerus or intermuscular septum or to the medial epicondyle of the humerus (Bergman et al, 1988).

* Correspondence to: **Dr. Kumar MR Bhat.** Dept. of Anatomy, Kasturba Medical College, Manipal University, Manipal-576104, India. kumar.mr@manipal.edu

Received: 29 January, 2013. **Revised:** 13 February, 2013. **Accepted:** 2 March, 2013.

Such variations are imperative when clinical diagnosis and surgical procedures are concerned. Even though, there are few reports to show the variations in the insertion pattern of the pectoralis major muscle, the present finding is

found to be unique and not been reported earlier. Such variations are of special interest while performing the reconstructive surgeries using pectoralis major muscles and while dealing with the neuromuscular compression in the arm.

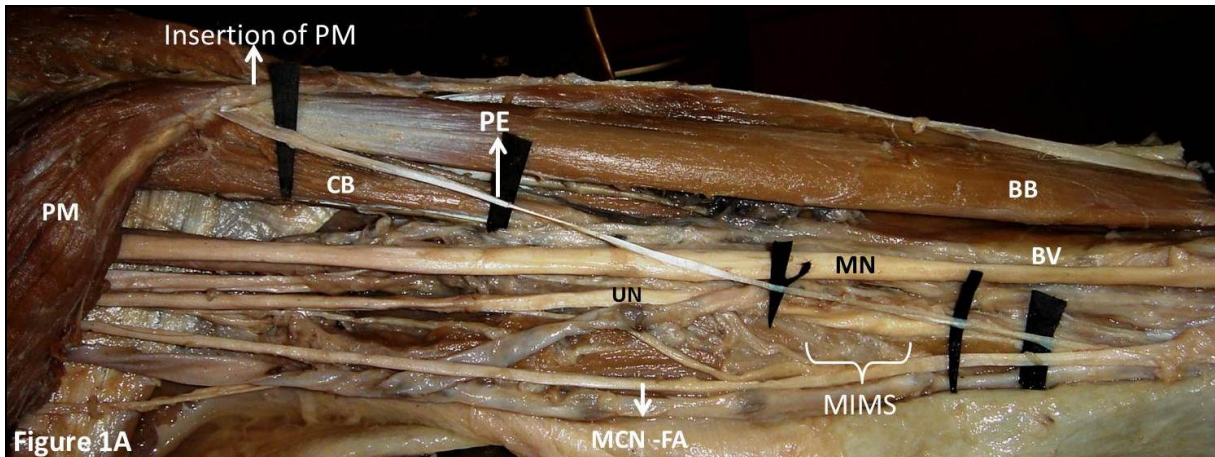


Figure 1A: A cadaveric dissection of the left arm showing a slender, shiny tendineous extension slip (PE) arising from the deep lamina of the bilaminar tendon of the pectoralis major muscle (PM). It crossed the biceps brachii (BB), coracobrachialis (CB), median nerve (MN), brachial vessels (BV) and ulnar nerve (UN) from the lateral to medial side and was blending with the medial intermuscular septum (MIMS) 2 cm above the medial epicondyle (ME) of the humerus before finally attached to it. MCN-FA: Medial cutaneous nerve of the forearm.




Figure 1B: A close-up view for the previous photograph showing the blending of the tendineous extension slip (PE) with the medial intermuscular septum (MIMS). BB: Biceps brachii muscle, MN: median nerve, UN: Ulnar nerve, BV: Brachial vessels, ME: Medial epicondyle.

CASE REPORT

During routine dissection of the left upper limb of a 55-year-old male cadaver, a slender, shiny tendinous extension slip proved to arise from the deep lamina of the pectoralis major's bilaminar tendon (Fig. 1A). This 0.3 mm width tendon then crossed the biceps brachii, coracobraccialis, median nerve, brachial vessels and ulnar nerve from lateral to medial to blend with the medial intermuscular septum 2 cm above the medial epicondyle of the humerus. Finally, it attached to the medial epicondyle of the humerus (Fig. 1B). On tracing this tendinous extension slip proximally, no associated separate muscular extension on to the chest wall could be observed. Since this extension was found to be arising from the pectoralis muscle itself near its insertion and not as additional muscle belly from the chest wall, the present variant tendon may be called as pectoro-epichondylaris.

DISCUSSION

Variations in the pectoral musculature have long been reported (Standering, 2005). The pectoralis muscle shows a special degree of variability in terms of its attachments and also with separate aberrant slips (Bergman et al, 1988). Although the data concerning anatomical variations of the pectoralis major muscle, it is crucial to continue describing newer and rarer variations as they arise. Variant muscles are usually asymptomatic but are of academic interest. They may present as a surgical problem if they cause symptoms.

A complete or partial absence of pectoralis major muscle has also been reported (Standering, 2005; Beals and Crawford, 1976). Bilateral absence of the normal twisted insertion of pectoralis major muscle has been stated by Flaherty et al (1999). Anomalous insertion of the pectoralis major into the shoulder joint capsule was also identified (Tubbs et al, 2008).

Pectoralis quartus, another variation usually arises near the costochondral junction of the fifth and sixth ribs, extends laterally and separately along the border of pectoralis major and is finally inserted into the deep surface of the pectoralis major muscle (Bergman et al, 1988). The origin and insertion of the quartus are frequently joined by a common band of connective tissue to an axillary arch or to a sternalis muscle when these muscles are present (Bergman et al, 1988). In a case report by Bonastre and his co-workers (2002), the pectoralis quartus originated from the rectus sheath, and joined the inferior medial border of the fibrous band of the axillary arch, at

the lateral edge of the pectoralis major. Co-existence of the pectoralis quartus and pectoralis intermedius muscles has also been reported. The pectoralis intermedius muscle was a fleshy slip between the pectoralis minor and pectoralis quartus muscles and arose from the third and fourth ribs which united to the tendon of the short head of the biceps brachii muscle two centimeters below the coracoid process (Arican et al, 2006).

An accessory head of the pectoralis major muscle arising from of the serratus anterior muscle and fusing with the tendinous fibers of the pectoralis major muscle is reported (Loukas et al, 2006). An unilateral four-headed pectoralis major muscle was also observed on the left side of an 83 year-old, caucasian male cadaver. The accessory tendon arose from the lateral aspect of the pectoralis major muscle, travelled with the tendon of the long head of the biceps brachii and was blending into the capsule of the shoulder joint (Hammad and Mohamed, 2006).

Chondro-fascialis is one such deviant slip that extends from the insertion of the pectoralis major to the medial intermuscular septum of the arm (Bergman et al, 1988; George and Jose, 2009). Costodorsalis, yet another muscular slip was also identified. This slip was originating from the 6th rib near the costochondral junction, running along the lower border of pectoralis major muscle, crossed the axilla from medial to lateral side and merged with the latissimus dorsi muscle (Shetty et al, 2011). Authors have also described the costo-epitrochlearis, chondro-epitrochlearis, or chondro-humeralis, arising from one or more ribs, crossing the axilla, and inserting into the medial intermuscular septum or medial epicondyle of the humerus (Bergman et al, 1988; Di Gennaro et al, 1998). Lama et al. (2010) reported the presence of chondro-humeralis and axillary arch of Langer; a rare combination of variant muscles with unique insertion. Similar findings were also reported by Loukas and his co-workers (2005), who preferred to rename the slip as thoraco-epicondylaris as it would accurately reflect the origin and insertion of the variant. The presence of chondro-epitrochlearis leading to neurological complications has been reported in two cases, in which surgical release was the only possible intervention (Spinner et al, 1991; Voto and Weiner, 1987).

Embryologically, the pectoral musculature is derived from dorsal limb bud masses. This mass of myoblasts arises from the C4-C8 and T1 myotomes during fifth week of intrauterine life (Sweeney, 1998, Turgut et al, 2000). On 47th day, the costal head of the pectoral mass splits into pectoralis minor and sternocostal part of pectoralis major muscle (Al Qattan et al, 2009)

The pectoral muscles then assume their final forms through a combination of migration, fusion and apoptosis of muscle cell precursors (Carlson, 2004). A slight alteration in the process may leave behind such aberrant muscle slips. The present variation may be due to failure in the migration of the few fibers of the pectoralis major muscle from its original insertion site or due to incomplete apoptosis of broad insertion of the pectoralis major muscle.

The present tendinous slip may lead to vascular and nerve entrapments and functionally limit the abduction of the humerus. A sound anatomical knowledge of the possible anomalous variations of the pectoral musculature may be of exceptional importance while treating the pectoralis major tear, while transforming the pectoralis major muscle during irreparable tare in the subscapularis muscle, while treating the calcic tendinopathy of the pectoralis major insertion, while using the pectoralis major muscle as myocutaneous flaps in reconstructive surgeries. In addition, such knowledge is also important to radiologists, neurologists, physiotherapists, orthopedicians, traumatologists and specialists in sports medicine. The knowledge of this particular variation may be imperative for interpretation of magnetic resonance and for reconstructive surgeons who may find it useful to utilize these supernumerary slips during surgeries.

ACKNOWLEDGEMENT

We sincerely thank Dr. AS D'Souza, Head of the Dept. of Anatomy, Kasturba Medical College, Manipal for his cooperation and suggestions. Our thanks to Mr. Srinivasa Rao, Melaka-Manipal Medical College, Manipal for his valuable contribution in preparing this manuscript.

REFERENCES

- Al Qattan MM, Yong Y, Kpzin SH.* 2009. Embryology of the upper limb. *J Hand Surg* 34: 1342.
- Arican RY, Coskun N, Sarikcioglu L, Sindel M, Oguz N.* 2006. Co-existence of the pectoralis quartus and pectoralis intermedius muscles. *Morphologie* 90: 157-159.
- Bears RK, Crawford S.* 1976. Congenital absence of the pectoral muscle. *Clinical orthopaedics* 119: 166.
- Bergman RA, Thompson SA, Afifi AK, Saadeh FA.* 1988. Compendium of human anatomic variations. Urban and Schwarzenberg, Baltimore-Munich, pp 7-8.
- Bonastre V, Rodriguez-Niedenführ M, Choi D, Sanudo JR.* 2002. Coexistence of a pectoralis quartus muscle and an unusual axillary arch: case report and review. *Clin Anat* 15: 366-370.
- Carlson BM.* 2004. Human embryology and developmental biology. Mosby, pp 224-225.
- Di Gennaro GL, Soncini G, Andrisano A, Valdiserri L.* 1998. The chondro-epitrochlearis muscle: case report. *Chir Organi Mov* 83: 419-423.
- Flaherty G, O'Neill MN, Folan-Curran.* 1999. Bilateral occurrence of a chondro-epitrochlearis muscle. *J Anat* 194: 313-315.
- Hammad RB, Mohamed A.* 2006. Unilateral four-headed pectoralis muscle major. *Mcgill J Med* 9: 28-30.
- George MB, Jose MG.* 2009. Chondro-fascialis Versus Pectoralis Quartus. *Clin Anat* 22: 871-872.
- Lama P, Potu BK, Bhat KM.* 2010. Chondro-humeralis and axillary arch of Langer: a rare combination of variant muscles with unique insertion. *Rom J Morphol Embryol* 51: 395-397.
- Loukas M, Louis RG Jr, Kwiatkowska M.* 2005. Chondro-epitrochlearis muscle, a case report and a suggested revision of the current nomenclature. *Surg Radiol Anat* 27: 354-356.
- Loukas M, South G, Louis RG Jr, Fogg QA, Davis T.* 2006. A case of an anomalous pectoralis major muscle. *Folia Morphol (Warsz)* 65: 100-103.
- Spinner RJ, Carmichael SW, Spinner M.* 1991. Infraclavicular ulnar nerve entrapment due to a chondro-epitrochlearis muscle. *J Hand Surg Br* 16: 315-317.
- Standring S.* 2005. Gray's Anatomy. The anatomical basis of clinical practice, 39th ed, Churchill Livingstone, Elsevier, pp 833-834.
- Shetty SD, Nayak SB, Kumar N, Somayaji SN, Mohandas Rao KG.* 2011. Costodorsalis – an Additional Slip of Pectoralis Major Muscle - a Case Report. *Int J Morphol* 29: 409-411.
- Sweeney LJ.* 1998. Basic concepts in embryology. McGraw-Hill. pp 136-138.
- Turgut, H, Anil A, Peker T and Barut C.* 2000. Insertion abnormality of bilateral pectoralis minimus. *Surg Radiol Anat* 22: 55-57.
- Tubbs RS, Shoja MM, Shokouhi G, Loukas M, Oakes WJ.* 2008. Insertion of the pectoralis major into the shoulder joint capsule. *Anat Sci Int* 83: 291-293.
- Voto SJ, Weiner DS.* 1987. The chondro-epitrochlearis muscle. *J Pediatr Orthop* 7: 213-214.