

Case Report**COURSE OF THE MAXILLARY ARTERY THROUGH THE LOOP OF THE AURICULOTEMPORAL NERVE****Kavya Bhat, Sampath Madhyastha*, Balakrishnan R***Department of Anatomy, Kasturba Medical College, Bejai Campus, Mangalore, Manipal University, India***RESUMEN**

Las variaciones en el curso de la arteria maxilar se describen a menudo, con sus relaciones con el músculo pterigoideo lateral. En el presente caso informamos una variación exclusiva en el curso de la arteria maxilar que no fue publicada antes. En un cadáver masculino de 75 años arteria maxilar derecho estaba pasando por el bucle del nervio auriculo-temporal. La arteria meníngea media provenía de la arteria maxilar con un bucle del nervio auriculo-temporal. La arteria maxilar pasaba profunda con respecto al nervio dentario inferior pero superficial al nervio lingual. El conocimiento de estas variaciones es importante para el cirujano y también serviría para explicar la posible participación de estas variaciones en la etiología del dolor mandibular.

Palabras clave: *Nervio auriculotemporal; arteria maxilar; variaciones*

ABSTRACT

Variations in the course of the maxillary artery are often described with its relations to the lateral pterygoid muscle. In the present case we report a unique variation in the course of the maxillary artery which was not reported before. In a 75 years old male cadaver the right maxillary artery passed through the loop of the auriculotemporal nerve. The middle meningeal artery was arising from the maxillary artery within the nerve loop of auriculotemporal nerve. Further the maxillary artery passed deep to the inferior alveolar nerve but superficial to the lingual nerve. The knowledge of these variations is important for surgeons and it would also explain the possible involvement of these variations in etiology of the craniomandibular pain.

Key words: *Auriculotemporal nerve; maxillary artery; variations*

INTRODUCTION

Maxillary artery is one of the larger terminal branches of the external carotid artery, arises behind the neck of the mandible, within the substance of the parotid gland. It then crosses the infratemporal fossa to enter the pterygo-palatine fossa through pterygo-maxillary fissure. The course of the artery is divided into three parts by the lateral pterygoid muscle. The first (mandibular) part runs horizontally, parallel to and slightly below the auriculo-temporal nerve. This part of the artery runs superficial (lateral) to the lower head of lateral pterygoid muscle. The second (pterygoid) part passes between the two heads of lateral pterygoid muscle to reach the pterygo-maxillary fissure before it passes into the pterygo-palatine fossa, where it finishes as the third (pterygo-palatine) part of the maxillary artery (Standring, 2008).

Anatomical variation in the course of the maxillary artery might complicate major procedures such as radical maxillectomy and minor procedures such as nerve blocks (inferior alveolar or lingual nerve).

* Correspondence to: **Sampath Madhyastha**, Department of Anatomy, Kasturba Medical College, Bejai Campus, Mangalore, Manipal University, India. sampath.m@manipal.edu

Received: 9 September, 2013. **Revised:** 21 October, 2013. **Accepted:** 8 November, 2013.

Maxillary artery and its variations is of great importance while performing surgeries on face, intra-arterial chemotherapy for head and neck cancers, diagnosis and treatment for diseases appearing in the maxillary artery dominating

regions (Otake et al, 2011). Here we report a case where the maxillary artery had a unique course which was not documented before, to the best of our knowledge.

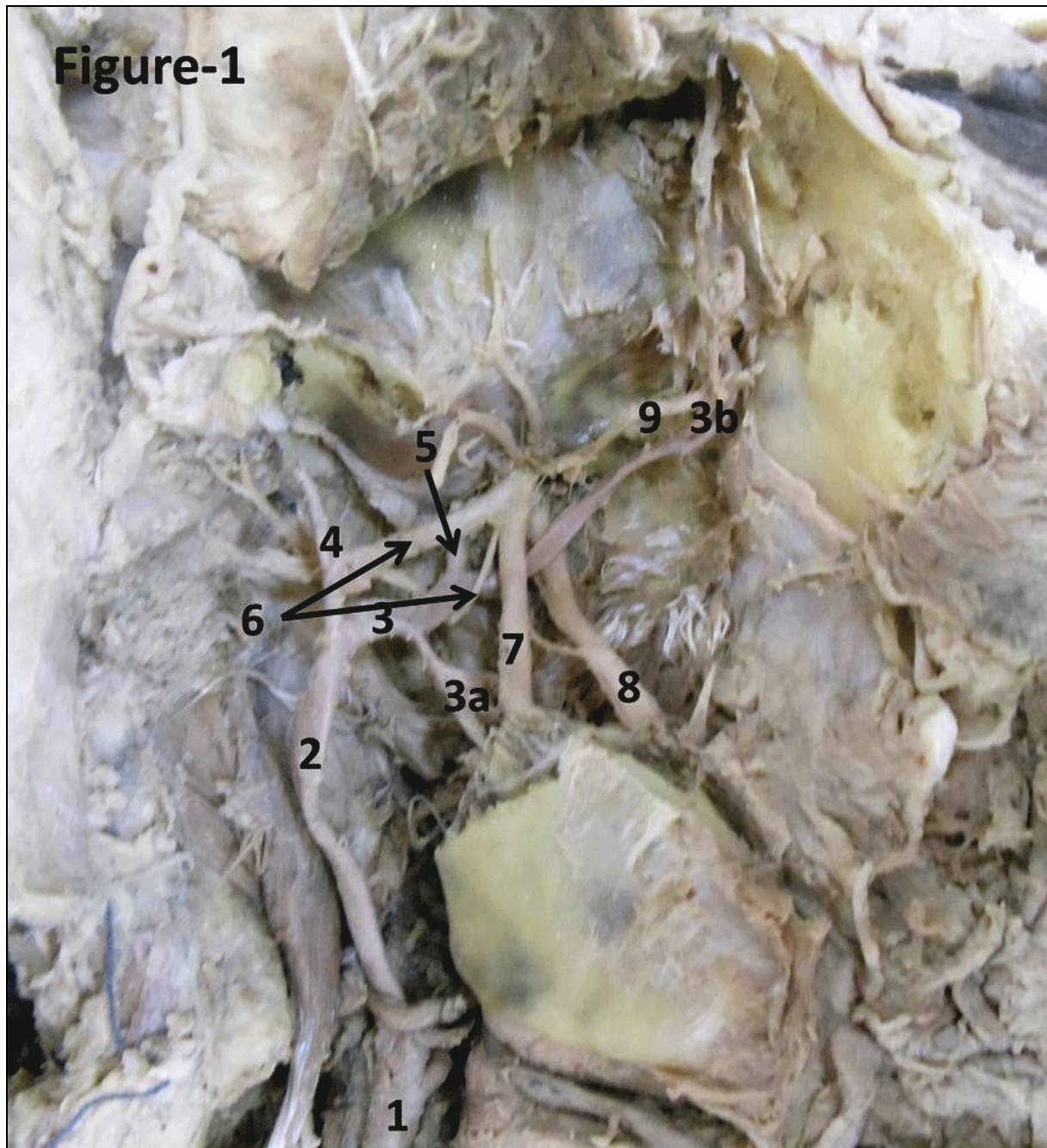


Figure 1 - 1-Common carotid artery, 2-External carotid artery, 3-First part of Maxillary artery, 3a-Inferior alveolar artery, 3b-Second part of maxillary artery, 4-Superficial temporal artery, 5-Middle meningeal artery, 6-Loop of the auriculotemporal nerve, 7-Inferior alveolar nerve, 8-Lingual nerve, 9-Buccal branch of the mandibular nerve.

CASE REPORT

This variation in the course of maxillary artery was observed during routine dissection in the department of anatomy, Kasturba Medical College, Mangalore in a 75 year old male cadaver and the cause of death and patient's history is unknown. Zygomatic arch was divided, masseter stripped from the ramus of the mandible exposing the temporalis. Further separating the coronoid process from the mandible, neurovascular bundle and deeper structures of the infratemporal fossa were dissected carefully and variations were noted and recorded using a digital camera.

The origin of the maxillary artery on the right side was normal and it passed deep to the lower head of the lateral pterygoid muscle (the muscle had been removed), then the artery passed through the loop of the auriculo-temporal nerve where it gave the middle meningeal artery (Fig.1). The maxillary artery proceeded forward, deep to the inferior alveolar nerve and superficial to the lingual nerve and finally entered the pterygo-maxillary fissure. The auriculo-temporal nerve is formed by thick superior root and thin inferior root passing the maxillary artery between them and also the origin of middle meningeal artery. The buccal branch of mandibular nerve passed deep to the deep temporal nerve and superficial to the third part of maxillary artery (Figure 1). A communication was noticed between the inferior alveolar and the lingual nerve. The other branching pattern of maxillary artery and mandibular nerve was found to be normal and no similar anomaly was observed on the left side.

DISCUSSION

The origin of maxillary artery is usually constant, but very rarely it arises as a branch of the facial artery piercing the medial pterygoid muscle in its upward course into the zygomatic fossa (Bergman et al, 1988). According to Susan Standing (2008) the first part of maxillary artery passes between the neck of mandible and sphenomandibular ligament parallel to and slightly below auriculo-temporal nerve but in the present case the artery was passing through the loop of auriculo-temporal nerve. Maxillary artery then passed deep to lateral pterygoid muscle. It is often seen superficial to the branches of mandibular nerve but in the present case the artery was passing deep (medial) to inferior alveolar nerve, superficial (lateral) to lingual nerve and superficial (lateral) to the buccal branch of mandibular nerve.

Variations in the course of the maxillary artery were mainly focused on its relation to the lower head of the lateral pterygoid muscle. According to Compendium of Human Anatomic variation by Bergman et al (1988) the maxillary artery was found medial to the lateral pterygoid muscle in 30.5% of the cases and lateral to it in 69.5%. In another study, the maxillary artery was deep (medial) to the lateral pterygoid muscle in 46% of 447 dissections and superficial (lateral) to it in 54% (Bergman et al). In a study by Uysal et al (2011) the maxillary artery was found superficial (lateral) to the lateral pterygoid muscle in 57.2% of the cases. In another study by Hussain et al (2008) the artery was found lateral to the lower head of the lateral pterygoid muscle (71% in men and 65% in women) and medial to the lower head of the lateral pterygoid muscle in only 14 of the cases (29% in men and 35% in women). The results of all these studies are consistent and help to conclude that the maxillary artery more often passed superficial (lateral) to the lower head of the lateral pterygoid muscle on its way to pterygo-palatine fossa. Further referring to the relations of maxillary artery to the branches of the mandibular nerve, the commonest pattern was the artery passing lateral to the inferior alveolar and lingual nerves (Standing, 2008).

An interesting report about the bifurcation of maxillary artery into unequal superficial (larger) and deep (smaller) divisions was reported by Claire et al (2011) where the superficial and deep divisions joint to form a complete loop, before giving the terminal branches in the pterygo-palatine fossa. The entire arterial loop lied superficial to the branches of the mandibular nerve. Quain reported a case cited by Bergman et al (1988) about the maxillary artery providing two branches that entered the cranial cavity (one branch through the foramen rotundum and the second through the foramen ovale) to compensate for the absence of the internal carotid artery.

Variations in the course of the maxillary artery are of importance in many surgical procedures. Refractory epistaxis is managed by ligation of the sphenopalatine artery via a transmaxillary - transantral approach; there is a considerable risk of complications associated with such invasive surgical approaches added on by variations in the course of the maxillary artery (Kwak et al, 2010). In cases of persistent epistaxis angiography guided arterial embolization of maxillary artery is mentioned as an efficient, alternate method to arterial ligation (Uysal et al, 2011) but knowledge of variations in the course of the artery is also important.

The role of hypertrophy of the two bellies of the lateral pterygoid muscles is assessed in the

etiology of craniomandibular pain and vascular headache. There were noted signs of vascular stenosis due to mechanical compression within the infratemporal fossa. The effect of this vascular flow disturbance resulted in ischemia to the gasserian ganglion and the duramater. Mechanical stimulation of the maxillary artery and its branches also contributed to pain development (Kolotyluk, 2013). In the present case similar complaints could have manifested by traction pressure on maxillary artery by the loop of the auriculo-temporal nerve. It is also possible that the traction pull of the auriculo-temporal nerve by maxillary artery could manifest as pain in the area of the distribution of auriculo-temporal nerve. Such variation could explain the cause of undiagnosed persistent pain rather than any pathological causes.

The Auriculo-temporal nerve usually arises by two roots from the posterior division of the mandibular nerve, which encircles the middle meningeal artery. It runs back under lateral pterygoid on the surface of tensor velopalatini, passes between the sphenomandibular ligament and the neck of the mandible and then runs laterally behind the temporomandibular joint (Standring, 2008). Except for the study by Gulecon et al, (2005) the variations in the formation of auriculo-temporal nerve was never reported. However there are reports about its connections with other branch of the mandibular nerve like inferior alveolar nerve (Racz et al, 1981). Variety of communication between the auriculotemporal and facial nerves were reported by Namking et al (1994).

In a cadaveric study of the auriculo-temporal nerve in the infratemporal fossa conducted by Gulecon et al (2005) variations in the number of roots have been reported but did not mention the course of maxillary artery.

Tumours arising or extending into the infratemporal fossa via foramen ovale or foramen rotundum, such as juvenile nasopharyngeal angiofibromas, are commonly excised by infratemporal approaches (Hussain et al, 2008). In these approaches, the entire contents of the infratemporal fossa are exposed, including the maxillary artery and its branches along with the mandibular nerve and its divisions, which may be greatly susceptible to damage or sacrifice. Therefore, knowing the course of the maxillary artery and its variations will aid in surgical planning and in minimizing intraoperative or postoperative complications. The embryological basis of this variation can be explained as follows. Maxillary artery is formed by a vascular network in the pterygoid mass of myoblast (Blermann, 1943). In the embryo the branches of the mandibular nerve pass through vascular

network formed by the developing maxillary artery. Later some part of these capillary network disappears and the remaining capillaries pass either superficial or deep to the maxillary artery. It is possible that the hemodynamic factors under the influence of the pterygoid are also responsible for the final course of the maxillary artery. It seems that some of the capillaries that passed through the branches of the mandibular nerve persisted leading to the formation of maxillary artery that passed between the two roots of auriculotemporal nerve.

Maxillary artery being a major arterial system in a deeper region of the head and any variation is worth noting to etiology of the mandibular pain as well as surgical procedures.

Maxillary artery being a major arterial system in a deeper region of the head and any variation is worth noting in etiology of the mandibular pain as well as surgical procedures.

REFERENCES

- Bergman RA, Adel K. Affi, AK, Miyauchi R.* 1988. Illustrated Encyclopedia of Human Anatomic Variation: Opus II: Cardiovascular System: Arteries: Head, Neck, and Thorax. Urban and Schwarzenberg. <http://www.anatomyatlases.org/AnatomicVariants/Cardiovascular/Text/Arteries/Maxillary.html>
- Blermann H.* 1943. DeChirurgische-Bedeutung der Lagevariationen der Arteria Maxillaris. *Anat Anz* 94:289-309
- Claire PG, Gibbs K, Hwang SH, Hill RV.* 2011. Divided and reunited maxillary artery: developmental and clinical considerations. *Anat Sci Int* 86: 232-236.
- Gulekon N, Anil A, Poyraz A, Peker T, Turgut HB, Karakose M.* 2005. Variations in the anatomy of the auriculotemporal nerve. *Cinc Anat* 18: 15-22.
- Hussain A, Binahmed A, Karim A, Sándor GKB.* 2008. Relationship of the maxillary artery and lateral pterygoid muscle in a Caucasian sample. *Oral Surg Oral Med Oral Pathol Oral Radiol Endod* 105: 32-36.
- Kolotyluk DR.* 1997. Mechanical stenosis of the maxillary artery in the infratemporal fossa: An etiology of craniomandibular pain and vascular headache. Department of Radiology and Diagnostic Imaging Edmonton: University of Alberta. www.collectionscanada.gc.ca/obj/.pdf. Last accessed on 12/ 03/ 2013.
- Kwak HH, Jo JB, Hu Ks, Oh CS, Koh Ks, Chung IH.* 2010. Topography of the third portion of the maxillary artery via the transantral approach in Asians. *J craniofac surg*, 21: 1284-1289.

- Namking M, Boonruangsri P, Woraputtaporn W, Guldner FH.* 1994. Short Report Communication between the facial and auriculotemporal nerves. *J Anal*, 185: 421-426.
- Otake, Ippeikageyama, Ikuomataga, Izumi.* 2011. Clinical anatomy of the maxillary artery. *Okajimas folia anatomica Japonica* 87: 154-164.
- Racz L, Maros T, Seres-Sturm L.* 1981. Anatomical variations of the nervus alveolaris inferior and their importance for the practice. *ANAT ANZ* 149: 329-332.
- Standing S.* 2008. *Gray's Anatomy*. 40thedn, Spain: Elsevier Limited, 540-1.
- Uysal Il, Buyukmumcu M, Dogan NU, Seker M, Ziyilan T.* 2011. Clinical Significance of Maxillary Artery and its Branches: A Cadaver Study and Review of the Literature. *International Journal of Morphology* 29: 1274.