

Reviews

A RARE CASE OF BILATERAL FLEXOR CARPI ULNARIS VARIATION: ANATOMICAL AND CLINICAL CONSIDERATIONS AND LITERATURE REVIEW

Alexandar Iliev¹, Georgi P. Georgiev², Boycho Landzhov¹

¹Department of Anatomy, Histology and Embryology, Medical University Sofia, Bulgaria

²Department of Orthopedics and Traumatology, University Hospital Queen Giovanna, Medical University Sofia, Bulgaria

RESUMEN

Varios músculos y estructuras fibro-tendinosas aberrantes se han identificado en la parte anterior de la muñeca, muchas de las cuales se considera que pueden causar síndromes de compresión neurovascular. A continuación describimos una estructura relacionada con el músculo flexor carpi ulnaris. Durante disecciones de rutina de ambos miembros superiores de cadáveres de adultos fue descubierta una estructura fibro-tendinosa con forma de medialuna en ambos miembros originando de la parte lateral del tendón distal del flexor carpi ulnaris. Esta estructura formaba un arco pasando sobre y cubriendo la arteria y el nervio ulnar antes de que entren en el canal de Guyon, y sobre el nervio mediano justo antes de que entre en el canal carpal. Este arco fibro-tendinoso seguía estrechándose hasta entrelazarse con el ligamento transversal del carpo y las fibras longitudinales de la aponeurosis palmar. En este mismo caso el músculo palmaris longus estaba ausente en ambas manos. Esta conexión entre el arco fibro-tendinoso y el nervio mediano, la arteria y el nervio ulnar en la muñeca posiblemente puede causar compresión neurovascular durante cierta actividad muscular.

Palabras clave: *músculo flexor carpi ulnaris; variación; significado clínico*

ABSTRACT

Various aberrant muscles and fibro-tendinous structures have been identified in the anterior wrist, some of them blamed to be possible causes for neurovascular compression syndromes. Herewith, we describe such an intriguing structure related to the flexor carpi ulnaris muscle. During routine dissection of both upper limbs of an adult cadaver, an interesting

crescent-shaped fibro-tendinous structure was identified bilaterally, arising broadly from the lateral side of the distal tendon of the flexor carpi ulnaris. This aberrant structure arched over the ulnar artery and nerve before they enter the canal of Guyon and the median nerve just before the carpal tunnel. Further distally, the fibro-tendinous arch narrowed and interlaced with the flexor retinaculum and palmar aponeurosis longitudinal fibres. In this case there was also concomitant bilateral absence of the palmaris longus muscle. Because this aberrant fibro-tendinous arch has very close relations to the median nerve, and ulnar nerve and artery in the wrist, it may possibly cause neurovascular compression during some muscle activity.

Key words: *flexor carpi ulnaris muscle; variation; clinical significance*

INTRODUCTION

Variations of the muscles, arteries and nerves of the upper limb are not uncommon and have been well documented in the literature (Georgiev et al, 2008a; Wadhwa et al, 2008; Georgiev et al, 2009a; Iliev et al, 2015; Slavchev and Georgiev, 2015).

* Correspondence to: **Georgi P. Georgiev, MD, PhD.** Department of Orthopaedics and Traumatology, University Hospital Queen Giovanna – ISUL, Medical University - Sofia, ul. Bialo more 8, BG 1504 Sofia, Bulgaria. georgievgp@yahoo.com

Received: 3 May, 2016. **Revised:** 16 May, 2016. **Accepted:** 28 May, 2016

Among them, variations of the flexor carpi ulnaris muscle are rarely described in the literature. They included aberrant proximal and/or distal attachment, various numbers of muscle bellies, as well as an accessory flexor carpi ulnaris muscle (Testut, 1928; O'Hara and Stone, 1988; Pribyl and Moneim, 1994; Vollala et al, 2008; Georgiev et al, 2009b; Ang et al, 2010; Bergman et al, 2016). Variations of the flexor carpi ulnaris, as well as variations of the palmaris longus are not only interesting from anatomical point of view, but also could have possible clinical significance (Harrelson and Newman, 1975; Chalmers, 1978; Seyhan, 2005; Georgiev et al, 2009b). Most commonly different muscular variations of the anterior wrist region are asymptomatic, but they

rarely could provoke pain, ulnar and median nerve compression or presenting as a soft tissue mass (Al-Qattan and Duerksen, 1992; Georgiev et al, 2008b; Georgiev et al, 2009c; Campos et al, 2010; Georgiev et al, 2010; Bhardwaj et al, 2013).

Herein, we present a rare case of bilateral flexor carpi ulnaris variation, namely the presence of a fibro-tendinous structure, arising from the lateral side of the distal tendon of the muscle, passing over the median nerve and ulnar nerve structure and inserted into the flexor retinaculum and the distal part of the palmar aponeurosis. We also made a brief literature review concerning the presented anatomical variations and their possible clinical significance.

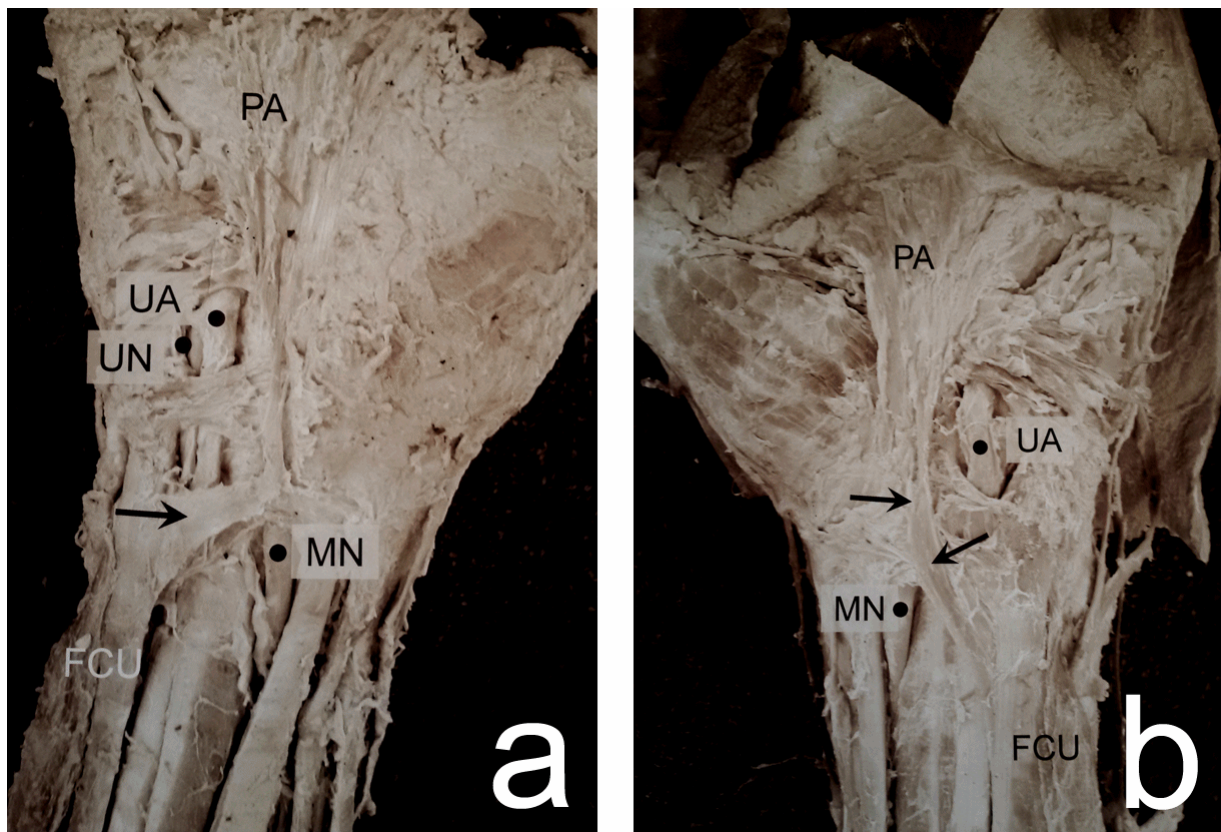


Figure 1- Photograph of the wrist and hand. a) right hand; b) left hand. Muscle: flexor carpi ulnaris, FCU. Nerves - UN, ulnar nerve; MN, median nerve; Arteries - UA, ulnar artery; Palmar aponeurosis - PA.

MATERIAL AND METHODS

During a routine anatomical dissection (approved by the Medico-Legal Office and Local Ethic Committee) of the upper limbs of a 69 years old Caucasian female cadaver, from the autopsy material available at the Department of Anatomy,

Histology and Embryology at the Medical University of Sofia, a rare case of bilateral variation of the flexor carpi ulnaris muscle was found. It was one of a series of 112 dissected cadavers, examined over a 25 years period. Skin and fat tissue were dissected, layer-by-layer, and lifted to expose the underlying

superficial flexor muscles. The subcutaneous veins and nerves were observed. Then, we dissected the humeral and ulnar heads of the flexor carpi ulnaris muscle and demonstrated the direction and location of the ulnar artery and nerve. Photographs were taken to document the observed variation of the distal tendon of the flexor carpi ulnaris.

RESULTS

In the present case, the variation was observed in both upper limbs. In the right upper limb, the flexor carpi ulnaris originated in a usual way, with two heads – humeral and ulnar. They formed a singular muscle belly, which continued into a strong tendon and inserted onto the pisiform bone. A fibro-tendinous band was noted in the distal part of the tendon, extending from its lateral side and after a short transverse course inserted into the distal portion of the palmar aponeurosis. It originated at a right angle and had a length of approximately 2.2 cm. It arched over the ulnar artery and nerve just before they entered the canal of Guyon and the median nerve just before the carpal tunnel. The fibro-tendinous band then interlaced with the flexor retinaculum and the palmar aponeurosis. The ulnar artery was positioned superficially and laterally to the ulnar nerve (Figure 1a). We also observed a concomitant absence of the palmaris longus muscle. The aberrant structure had no relation to the underlying tendons of the other superficial flexor muscles. Its appearance suggested that it was built of dense fibrous connective tissue, resembling the structure of the neighbouring tendons of other superficial flexor muscles.

In the left upper limb the flexor carpi ulnaris muscle also originated with two heads – humeral and ulnar. After a very short course, these heads formed a singular body, which continued into the distal tendon of the muscle in the lower part of the forearm and inserted onto the pisiform bone. We observed the presence of a fibro-tendinous bundle, which originated from the lateral side of the distal portion of the tendon of the flexor carpi ulnaris. It followed an oblique course and had a length of approximately 3.5 cm. After arching over the underlying ulnar artery and nerve, and the median nerve, this structure inserted into the distal part of the palmar aponeurosis at the level of the carpal canal and the flexor retinaculum. The aberrant structure also appeared to form a thin separate protrusion that inserted into the middle part of the palmar aponeurosis (Figure 1b). Again, we noted the concomitant absence of the palmaris longus muscle. The bundle had no

relation to the underlying tendons of the other superficial flexor muscles. We deduced that it was built of dense fibrous connective tissue.

The innervation of the variant flexor carpi ulnaris muscle was from the ulnar nerve. The division and course of the ulnar artery was as usual. No other variations of both upper limbs were observed. The information concerning history of previous diseases for the dissected subject missed. No clinical signs of trauma or surgical scars were noticed.

DISCUSSION

Anomalies of the flexor carpi ulnaris muscle are usually considered to be rare. According to one study, no variations of this muscle were found among 5,000 cadavers (Ang et al, 2010). Generally, the following groups of variations have been established: a) variations in the muscular-tendinous junction of the flexor carpi ulnaris (Grechenig et al, 2000); b) variant flexor carpi ulnaris causing ulnar nerve compression (Al-Qattan and Duerksen, 1992) and c) an additional slip of the flexor carpi ulnaris (Macalister, 1875; Vollala et al, 2008). Another classification determined the following groups of anomalies involved in the presence of supernumerary flexor carpi ulnaris: type 1 - a single muscle with two tendons (split tendon); type 2 - each head forming a separate muscle and tendon (digastric flexor carpi ulnaris) and type 3 - an extra muscle in addition to normal flexor carpi ulnaris (an accessory flexor carpi ulnaris) (Bhardwaj et al, 2013). Reported anatomical variations of the flexor carpi ulnaris include extratendinous bands from the tendon of the flexor carpi ulnaris to the fourth or fifth metacarpal bone, duplication of the distal tendon, a fibrous or muscular extension from the tendon of the flexor carpi ulnaris to the carpal ligaments, an additional abductor digiti minimi muscle originating from the flexor carpi ulnaris (Georgiev et al, 2009b) and an accessory flexor carpi ulnaris muscle originating from the medial epicondyle and the antebrachial fascia and inserting onto the pisiform bone (Arnold and Zech, 1977). A digastric variant of the flexor carpi ulnaris has been also described in literature consisted of separate humeral and ulnar muscle bellies that formed separate tendons, which fused shortly before the insertion on the pisiform bone (Rao et al, 2009; Pugh et al, 2010).

The variation presented herein can be described as an additional fibro-tendinous band originating from the distal tendon of the flexor carpi ulnaris muscle, arching over the underlying ulnar artery and nerve and the median nerve and inserting

into the flexor retinaculum and the palmar aponeurosis. There was also a concomitant bilateral absence of the palmaris longus muscle. This rare bilateral anomaly is most likely caused by currently unknown genetic factors. To our knowledge, this is the first time that the presence of an aberrant fibro-tendinous band originating from the distal tendon of the flexor carpi ulnaris muscle and the concomitant absence of a palmaris longus muscle has been reported in literature. Our hypothesis is that this fibro-muscular band, extending from the tendon of the flexor carpi ulnaris muscle probably compensates for the lack of palmaris longus muscle and strengthens the flexor retinaculum, thus supporting the function of the muscles of the forearm.

Among the different variations of the palmaris longus muscle, its agenesis is the most common one (Yildiz et al, 2000; Natsis et al, 2007; Georgiev et al, 2008c; Iliev et al, 2012). It was proven to be hereditary (Danforth, 1924), although the pattern of inheritance has not been established as of yet. It has limited action in carpal flexion; therefore its absence does not lead to loss of function in the forearm or hand and has limited clinical significance.

The presence of aberrant structures in the forearm and wrist is known to be an important factor for the development of syndromes of nerve and vessel compression (Georgiev and Jeleu, 2007; Slavchev and Georgiev, 2013; Georgiev and Jeleu, 2011). The fibro-tendinous band reported herein arched over the ulnar artery and nerve just before they entered the canal of Guyon and the median nerve just before the carpal tunnel. It can therefore lead to compression or entrapment of vessel and/or nerve and cause clinical symptoms in the palmar region (Pugh et al, 2010). Reports in literature have pointed out that the presence of different anatomical variants of the flexor carpi ulnaris may cause ulnar nerve compression, including splitting of the nerve by lateral tendon duplication (Al-Qattan and Duerksen, 1992) and entrapment of the ulnar nerve due to division of the insertion of the muscle onto the pisiform bone (Zook et al, 1988), thus leading to significant neuropathies and distal dysfunction (Sunil and Chandrashekar, 2003). Additionally to nerve compression, an aberrant muscle may be also associated with thrombosis of the ulnar artery (Moss and Forthman, 2008).

Anomalies of the flexor carpi ulnaris can also be responsible for flexion deformities (Alvin et al, 2011). Patients can also present with symptoms of median nerve compression due to such aberrant structures, which can be misdiagnosed as resulting from more common causes, such as

radiculopathy and carpal tunnel syndrome (Vollala et al, 2008).

In the cases of nerve and artery compression by anomalous muscles, ultrasound imaging and/or MRI could be used as imaging modalities that could help in determining muscle variations (Zeiss et al, 1992).

In conclusion, clinical awareness of such variations of the flexor carpi ulnaris is important as they may cause symptoms of neurovascular compression of the ulnar artery and nerve and the median nerve, and can be misdiagnosed for more complex pathological causes. Furthermore, some of these variations might be showing a pattern of genetic inheritance which has not been extensively studied as of yet and deserves more attention in future research. In our review, we have supplemented the current classification while presenting a case of a bilateral aberrant fibro-tendinous band extending from the distal tendon of the flexor carpi ulnaris muscle and concomitant absence of palmaris longus muscle for the first time in literature.

Conflict of interest

None

Funding

None to be declared.

Ethic Approval

The medico-legal office and local Ethic Committee approved this study.

Informed Consent

All donors and their families had agreed to their use in medical and scientific research.

Contributions

These authors hereby confirm that the manuscript is original and have not been published and is not under consideration for publication elsewhere. The contributions of the authors are as described: AI and GPG conceived the article. AI wrote the article. GPG and BL helped in analysing the result section and preparing the manuscript. All authors have read and approved the final manuscript.

REFERENCES

Al-Qattan MM, Duerksen F. 1992. A variant of flexor carpi ulnaris causing ulnar nerve compression. J Anat 180: 189-90.

- Alvin M, Alan N, Leone J, Fredieu JR.* 2011. A unilateral accessory flexor carpi ulnaris muscle observed during cadaveric dissection. *Clin Anat* 24: 971-73.
- Ang GG, Rozen WM, Vally F, Eizenberg N, Grinsell D.* 2010. Anomalies of the flexor carpi ulnaris: Clinical case report and cadaveric study. *Clin Anat* 23: 427-30.
- Arnold G, Zech M.* 1977. An accessory muscle and additional variants of the forearm. *Handchirurgie* 9: 135-36.
- Bergman RA, Afifi AK, Miyauchi R.* 2016. Part I: Muscular system. In: *Illustrated encyclopedia of human anatomic variations*. <http://www.anatomyatlases.org/AnatomicVariants/AnatomyHP.shtml>
- Bhardwaj P, Bhandari L, Sabapathy SR.* 2013. Supernumerary flexor carpi ulnaris-case report and review. *Hand Surg* 18: 393-97.
- Campos D, Nazer MB, Bartholdy LM.* 2010. Accessory flexor carpi ulnaris muscle: a case report of a rare variation in human. *J Morphol Sci* 27: 30-31.
- Chalmers J.* 1978. Unusual causes of peripheral nerve compression. *Hand* 10: 168-75.
- Danforth CH.* 1924. The heredity of unilateral variations in man. *Gen* 9: 199-211.
- Georgiev GP, Jeleu L.* 2007. Variant triple origin of the flexor digiti minimi brevis (manus) muscle in relation to ulnar nerve and artery compression at the wrist. *Clin Anat* 20: 976-77.
- Georgiev GP, Jeleu L, Kinov P.* 2008a. Variations of the biceps brachii muscle in Bulgarian population and their significance for clinical practice. *Bulg J Orthop Trauma* 45: 129-34.
- Georgiev GP, Jeleu L, Surchev L.* 2008b. Variations of the hypothenar muscles. *Acta Morphol Anthropol* 13: 313-15.
- Georgiev GP, Jeleu L, Surchev L.* 2008c. Reversed palmaris longus muscle simulating soft-tissue mass as a possible cause of median nerve compression. *Bulg J Orthop Trauma* 45: 92-94.
- Georgiev GP, Dimitrova IN, Jeleu L, Marinova D.* 2009a. A case with aberrant origin of the brachial and antebrachial arteries and some remarks on the terminology of the upper limb variant arteries. *J Biomed Clin Res* 2: 172-73.
- Georgiev GP, Jeleu L, Ovtscharoff WA.* 2009b. Unusual combination of muscular and arterial variations in the upper extremity: a case report of a variant palmaris longus and an additional tendinous portion of the flexor carpi ulnaris together with a persistent median artery. *Anat* 3: 58-61.
- Georgiev GP, Jeleu L, Surchev L.* 2009c. Presence of a palmaris longus related variations in three members of a family. *J Hand Surg Eur Vol* 34: 277-78.
- Georgiev GP, Jeleu L, Kinov P.* 2010. Aberrant muscles at the Guyon's canal. *Int J Anat Var* 4: 67-69.
- Georgiev GP, Jeleu L.* 2011. An aberrant flexor digiti minimi brevis manus muscle. *J Hand Surg Am* 36: 1965-7.
- Grechenig W, Clement H, Egner S, Tesch NP, Weiglein A, Peicha G.* 2000. Musculo-tendinous junction of the flexor carpi ulnaris muscle. An anatomical study. *Surg Radiol Anat* 22: 255-60.
- Harrelson JM, Newman M.* 1975. Hypertrophy of the flexor carpi ulnaris as a cause of ulnar-nerve compression in the distal part of the forearm. Case report. *J Bone Joint Surg Am* 57: 554-55.
- Iliev A, Jeleu L, Landzhov B, Malinova L, Hinova-Palova D, Paloff A, Ovtscharoff W.* 2012. A doubled palmaris longus muscle: case report. *Acta Morphol Anthropol* 19: 78-80.
- Iliev A, Mitrov L, Georgiev GP.* 2015. A variation of the origin and course of the posterior circumflex humeral artery and the deep brachial artery. Clinical importance of the variation. *J Biomed Clin Res* 8: 164-67.
- Macalister A.* 1875. Additional observations on muscular anomalies in human anatomy (third series), with a catalogue of the principal muscular variations hitherto published. *Trans Roy Irish Acad* 25: 85-86.
- Moss DP, Forthman CL.* 2008. Ulnar artery thrombosis associated with anomalous hypothenar muscle. *J Surg Orthop Adv* 17: 85-88.
- Natsis K, Levva S, Totlis T, Anastasopoulos N, Paraskevas G.* 2007. Three-headed reversed palmaris longus muscle and its clinical significance. *Ann Anat* 189: 97-101.
- O'Hara JJ, Stone JH.* 1988. Ulnar neuropathy at the wrist associated with aberrant flexor carpi ulnaris insertion. *J Hand Surg Am* 13: 370-72.
- Pribyl CR, Moneim MS.* 1994. Anomalous hand muscle found in the Guyon's canal at exploration for ulnar artery thrombosis: A case report. *Clin Ortho Relat Res* 306: 120-23.
- Pugh AM, Silvestri AB, Ward AM, Whited WM, Capehart AA.* 2010. Unusual bilateral muscular variation in the medial forearm: separate humeral and ulnar bellies of flexor carpi ulnaris and anomalous muscle addition. *Anat* 4: 67-71.
- Rao MRK, Bhat SM, Venkataramana V, Rodrigues V.* 2009. Ulnar and humeral heads forming separate bellies. A rare case of digastrics flexor carpi ulnaris muscle. *Int J Morphol* 27: 31-34.
- Seyhan T.* 2005. Median nerve compression at the wrist caused by reversed 3-headed palmaris longus muscle: case report and review of the literature. *Am J Orthop* 34: 544-46.

- Slavchev SA, Georgiev GP.* 2013. Aberrant abductor digiti minimi muscle found during open surgical decompression of the carpal tunnel: case report. *Rev Arg Anat Clin* 5: 88-91.
- Slavchev SA, Georgiev GP.* 2015. Ultrasound diagnosis of a ganglionic cyst within an extensor digitorum brevis manus muscle. *Chir de la main*, 34: 269–71.
- Sunil TM, Chandrashekara S.* 2003. Congenital flexion deformity of the wrist owing to an anomalous insertion of the flexor carpi ulnaris: A case report. *J Hand Surg Am* 28: 866-70.
- Testut L.* 1928. *Traité d'anatomie humaine*. Tome I. Ostéologie – Arthrologie – Myologie. Paris: Gaston Doin & Cie, 1-1204.
- Vollala VR, Bhat S, Rodrigues V, Prasad D, Pamidi N.* 2008. Additional Muscle Slip of Flexor Carpi Ulnaris Associated with Anomalous Ulnar Nerve and Ulnar Artery in the Distal Forearm. *Int J Morphol* 26: 373-76.
- Wadhwa S, Vasudeva N, Kaul JM.* 2008. A rare constellation of multiple upper limb anomalies. *Folia Morphol (Warsz)* 67: 236-39.
- Yildiz M, Sener M, Aynaci O.* 2000. Three-headed reversed palmaris longus muscle: a case report and review of the literature. *Surg Radiol Anat* 22: 217-19.
- Zeiss J, Jakab E, Khimji T, Imbriglia J.* 1992. The ulnar tunnel at the wrist (Guyon's canal): normal MR anatomy and variants. *AJR Am J Roentgenol* 158: 1081-85.
- Zook EG, Kucan JO, Guy RJ.* 1988. Palmar wrist pain caused by ulnar nerve entrapment in the flexor carpi ulnaris tendon. *J Hand Surg* 13: 732-35.

ACKNOWLEDGEMENT

The authors are very indebted to Mr. Georgi Kotov for his kind proofreading to the English text. We would like to thank Mr. Joy Papingi for the Spanish translation of the text.