

Original Communications**MORPHOMETRIC STUDY OF THE JUGULAR FORAMEN IN DRY NIGERIAN SKULLS****Ukoha U. Ukoha¹, Chijioke M. Okeke¹, Chinwe Ukoha², Izuchukwu F. Obazie³, Henry C. Nwankwo¹, Jervas Ekezie⁴**¹*Department of Anatomy, Nnamdi Azikiwe University, Nnewi Campus, Nnewi, Nigeria.*²*Department of Microbiology, Chukwuemeka Odimegwu Ojukwu University, Uli Campus, Uli, Nigeria.*³*Chukwuemeka Odimegwu Ojukwu University, Uli Campus, Uli, Nigeria.*⁴*Department of Anatomy, School of Basic Medical Sciences, Federal University of Technology, Owerri, Nigeria***ABSTRACT**

Jugular foramen is a hiatus in the posterior cranial fossa that transmits the internal jugular vein among other structures. The knowledge of the jugular foramen is important in neurosurgical procedures. The objective of the study was to characterize the morphology and the dimensions of jugular foramen in dry Nigerian skulls. One hundred and seventy jugular foramens from 85 dry adult skulls of unknown sex were studied. Morphology was studied by observation and measurements were taken with Vernier caliper. The parameters that were studied included the shape, septation, medio-lateral diameter, antero-posterior diameter of jugular foramen, and the dome, width and depth of jugular fossa. Oval shaped foramen (77%) was more prevalent than round shaped foramen (23%). Complete septation was found in 19.4% of skulls, while incomplete septation was found in 41.2% of skulls. Absence of septation was found in 39.4% of skulls. Dome over the jugular fossa was present in 67.6% and absent in 32.4% of the skulls. The antero-posterior diameter (right - 13.20mm±2.8, left - 11.72 ±2.8) and medio-lateral diameter (right - 18.73mm ±3.5, left - 17.33mm±3.1) were significantly higher on the right side than on the left side. The depth of jugular fossa was significantly higher on the right side (12.38mm±2.4) than on the left side (10.95mm±2.8). The width of jugular fossa was higher on the right (12.06mm±3.6) than on the left (11.80mm±3.3) but the difference was not significant. The present study demonstrated right sided dominance in the metric parameters of the jugular foramen in our environment.

Key words: *morphometric; jugular foramen; Nigeria; skulls*

caracterizar la morfología y las dimensiones del foramen yugular en cráneos nigerianos secos. Cientos y setenta forámenes yugulares a partir de 85 cráneos secos del adulto de sexo desconocido fueron estudiados. La morfología fue estudiada por la observación y las medidas fueron tomadas con el calibrador de Vernier. Los parámetros que fueron estudiados incluyeron la forma, la tabicación, el diámetro medio-lateral, el diámetro anteroposterior del foramen yugular, y la bóveda, la anchura y la profundidad de la fosa yugular. El agujero de forma oval (el 77%) era más frecuente que el agujero de forma redonda (23%). La tabicación completa fue encontrada en 19,4% de cráneos, mientras que la tabicación incompleta fue encontrada en 41,2% de cráneos. La ausencia de tabicación fue encontrada en 39,4% de cráneos. La bóveda sobre la fosa yugular estaba presente en 67,6% y ausente en 32,4% de los cráneos. El diámetro anteroposterior (derecho: 13,20 mm±2,8, izquierdo: 11,72±2,8) y el diámetro medio-lateral (derecho: 18,73mm ±3,5, izquierdo: 17,33mm±3,1) eran perceptiblemente más altos en el derecho que en el lado izquierdo. La profundidad de la fosa yugular era perceptiblemente más alta en el derecho (12,38mm±2,4) que en el lado izquierdo (10,95mm±2,8). La anchura de la fosa yugular era más alta en la derecha (12,06mm±3,6) que a la izquierda (11,80mm±3,3) pero la diferencia no era significativa. El actual estudio demostró la dominación del lado derecho en los parámetros métricos del foramen yugular en nuestro medio.

Palabras claves: *morphometric; foramen yugular; Nigeria; cráneos*

RESUMEN

El foramen yugular es un hiato en la fosa craneal posterior que transmite la vena yugular interna entre otras estructuras. El conocimiento del foramen yugular es importante en procedimientos neuro-quirúrgicos. El objetivo del estudio era

* Correspondence to: **Chijoke M. Okeke.**
okeke.chijioke@yahoo.com

Received: 8 October, 2018. **Revised:** 31 October, 2018.
Accepted: 16 November, 2018.

INTRODUCTION

The jugular foramen is a large irregular hiatus that lies in the posterior cranial fossa at the posterior end of the petro-occipital suture (Standring, 2008; Pereira et al, 2010). It transmits the inferior petrosal sinus, the glossopharyngeal, vagus and spinal accessory nerves; and the internal jugular vein (Gupta et al, 2014).

Over the years, researchers have observed variations not only in the shape and dimensions of the foramen, but also in presence or absence of septations (Khanday et al, 2013). If septation exists, it is caused by the projection of intrajugular process (Gupta et al, 2014; Kumar et al, 2015), which divides the jugular foramen into neural and vascular compartments.

The jugular foramen is of clinical importance because of the important structures that traverse this hiatus. Some pathologic conditions can occur around this place. Glomus jugulare (Das et al 2016; Vlajkovic et al, 2010; Linn et al, 2009), schwannomas, meningiomas (Khanday et al, 2013), metastatic tumors and infiltrating inflammatory lesions can take place around the

jugular foramen. These lesions have tendency not only to affect the structures passing through but also to distort the anatomy of the jugular foramen. (Das et al 2016).

Keen knowledge of the jugular foramen is very essential for microsurgical procedures around this region. Ligation of the internal jugular vein during radical dissection of the neck may lead to venous infarction. This has been attributed to ligation of the 'dominant' internal jugular vein (Khanday et al, 2013). Anomalies of the jugular bulb are related to jugular foramen (Kumar et al, 2015). Distortion of the normal anatomy of the jugular foramen by pathological conditions may not allow correct visualization during surgery (Singla et al, 2012). Thus good knowledge of the morphology, dimensions and various variations of the jugular foramen would be essential in such surgical procedures.

Morphometric study of the jugular foramen is not common in our environment. The aim of this study was therefore to ascertain the peculiarities of the morphology and dimensions of the jugular foramen in our environment.

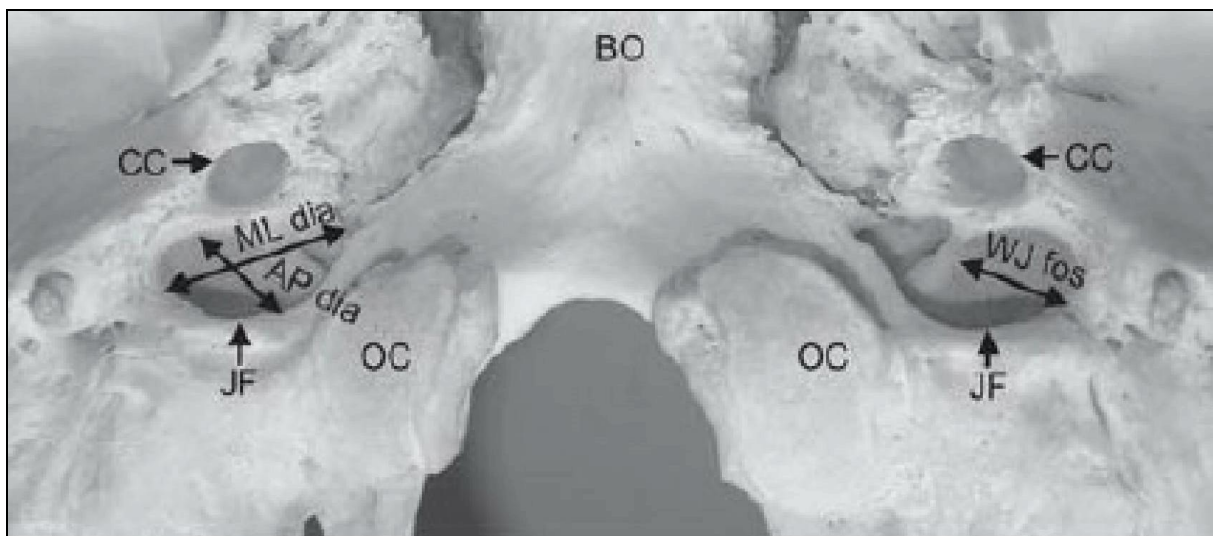


Figure 1: The skull showing mediolateral diameter, anteroposterior diameter, and width of jugular fossa (adapted from Singla et al, 2012). ML dia (medio-lateral diameter). AP dia (antero-posterior diameter). WJ fos (width of jugular fossa)

MATERIALS AND METHODS

One hundred and seventy (170) jugular foramina from eighty five (85) dry adult skulls of unknown sex were studied. The skulls were obtained from the anatomy departments of four (4) medical institutions in the South East and South South

geo-political regions of Nigeria. The skulls were normal and the jugular foramina were intact.

The measurements were taken with Vernier caliper (Gilson tools Japan, 0-150mm X 0.05/6" X 1/128), with precision of 0.05mm. Measurements were taken by the method described by Singla et al (2012).

Morphological study was done by inspection. The under listed parameters were studied from the jugular foramen and jugular fossa.

Jugular foramen:

- Sides: side was determined by placing the skull in anatomical position
- Shape: the shape was either oval or round

- Medio-lateral diameter (ML dia): This is the distance between the medial most and lateral most points of the jugular foramen when placed in anatomical position. (Figure 1)
- Antero-posterior diameter (AP dia): This is the maximum antero-posterior diameter when placed in anatomical position. (Figure 1)

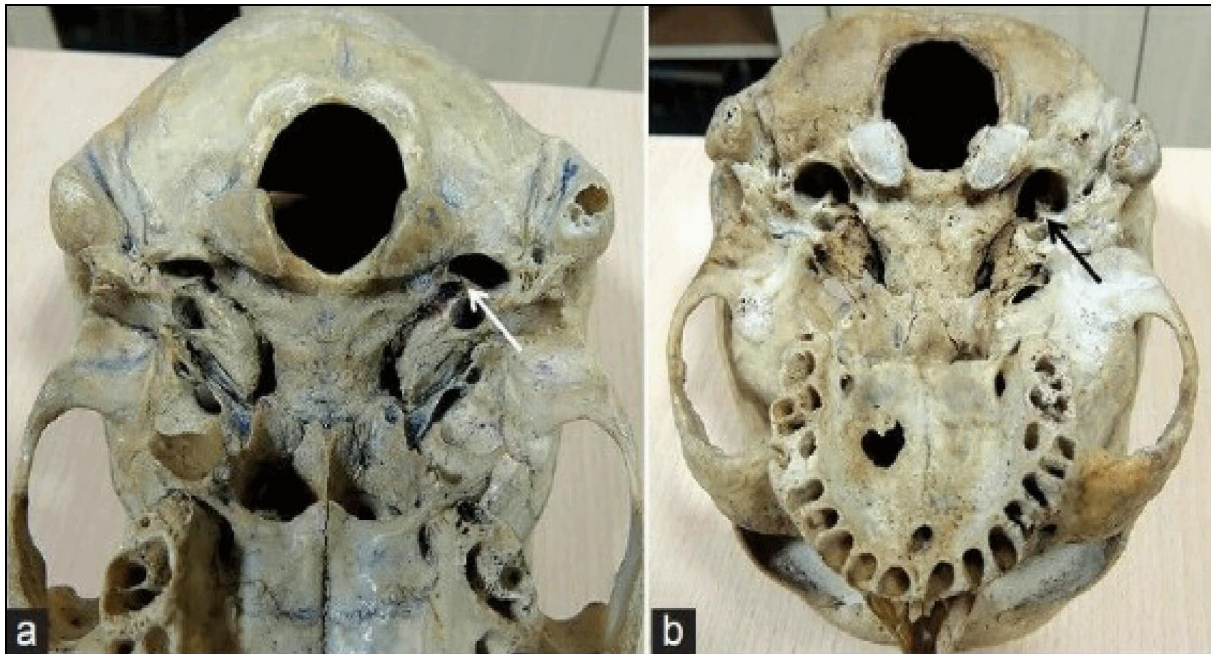


Figure 2: The skull showing septation of jugular foramen (adapted from Gupta et al 2014). (a) Complete septation. (b) Incomplete septation

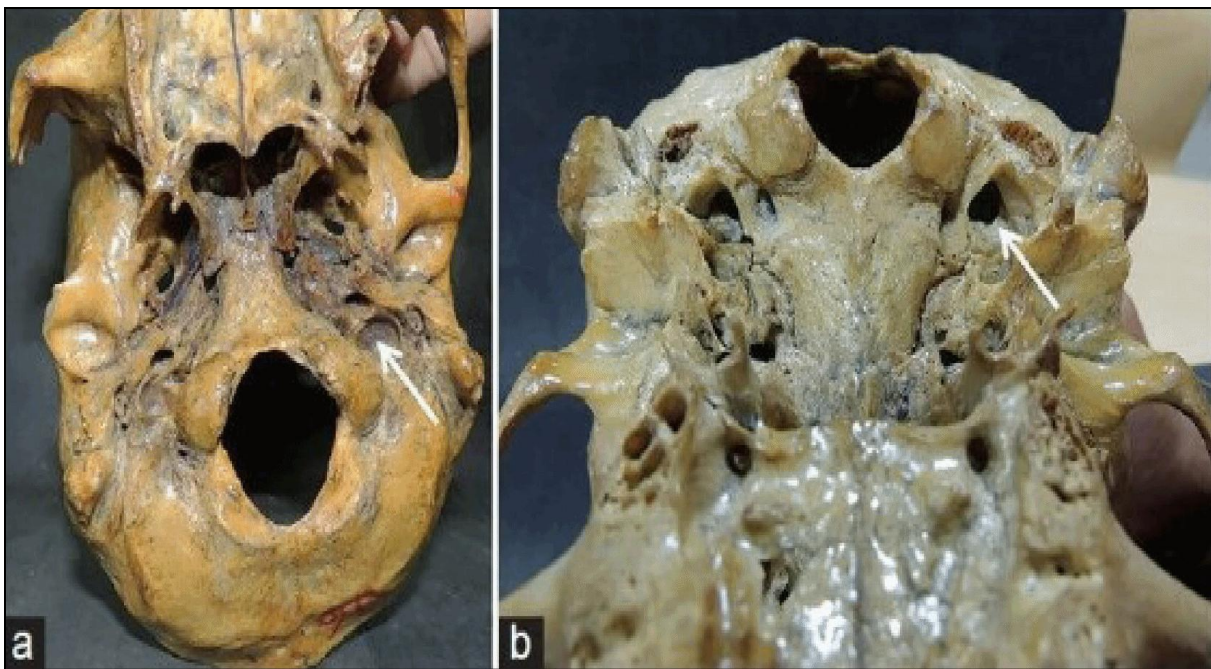


Figure 3: The skull showing dome over the jugular fossa (adapted from Gupta et al 2014). (a) Presence of dome. (b) Absence of dome

- Septation: presence or absence of bony ridge dividing the foramen into compartments was assessed. When present, we determined whether the compartments were complete or not and how many compartments were present. (Figure 2).

Jugular fossa:

- Dome: presence or absence of domed roof was observed. Presence of dome converts the foramen into fossa. (Figure 3)
- Width of jugular fossa (WJ fos): maximum width of jugular fossa was measured (Figure 1).

- Depth of jugular fossa (DJ fos): This is the distance from the summit of the dome to the inferior border of the jugular fossa.

Data were analyzed using Statistical Package for Social Sciences (SPSS) version 21 (IBM Corp. released 2012 IBM SPSS Statistics for Windows, Version 21.0. Armonk, NY: IBM Corp). Numerical data were expressed as means and standard deviation while categorical data were expressed as percentages. Comparative analysis was done. Test of significance was done using student's T test and level of significance was set at $p < 0.05$.

	Shape		Septation			Domed	
	N (%)		N (%)			N (%)	
	Oval	Round	Absent	Complete	Incomplete	Absent	Present
Left	57 (33.5)	28 (16.5)	31 (18.2)	19 (11.2)	35 (20.6)	16 (9.4)	69 (40.6)
Right	74 (43.5)	11 (6.5)	36 (21.2)	14 (8.2)	35 (20.6)	39 (23)	46 (27)
Total	131 (77)	39 (23)	67 (39.4)	33 (19.4)	70 (41.2)	55 (32.4)	115 (67.6)

Table 1: Morphological features of jugular foramen and jugular fossa.

RESULTS

Table 1 shows the summary of the shape, septation and domed features of the left and right jugular foramina. Oval shape was more prevalent than the round shape, and the predominant oval shape was more on the right than on the left.

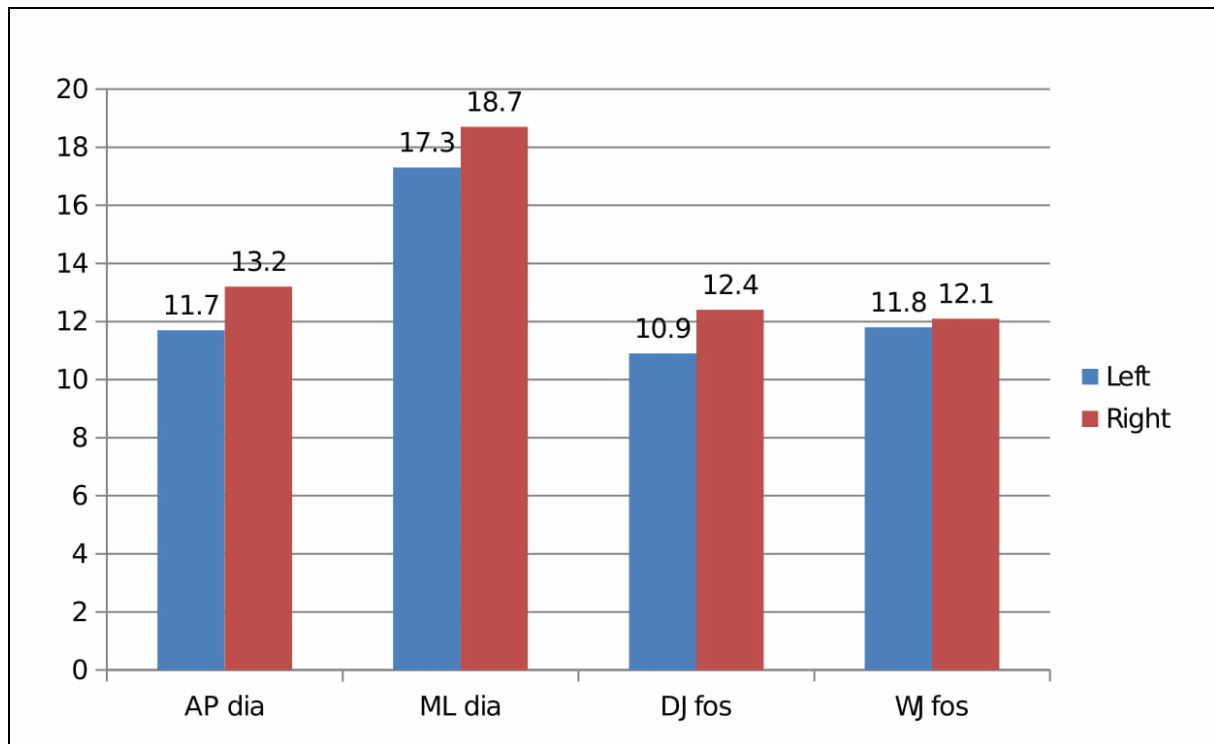
Presence of septation was more prevalent (60.6%) than absence of septation (39.4%). Among the jugular foramina with septations, incomplete septation was more prevalent (41.2%) than complete septation (19.4%); and this was equally distributed on either side. Presence of dome was more prevalent

than absence of it, and the presence of dome was more on the left side than the right side.

Graphic 1 shows the dimensions of metric parameters that were measured in the jugular foramen and jugular fossa. The mean values of AP dia (right - $13.20\text{mm} \pm 2.8$, left - 11.72 ± 2.8) and the mean values of ML (right - $18.73\text{mm} \pm 3.5$, left - $17.33\text{mm} \pm 3.1$) were significantly higher on the right than on the left side, with p values of 0.001 and 0.007 respectively. Taking both sides together, the mean value of AP dia was 12.5mm while the mean ML dia was 18mm.

The values of DJ fos (right - $12.38\text{mm}\pm 2.4$, left - $10.95\text{mm}\pm 2.8$) and WJ fos (right - $12.06\text{mm}\pm 3.6$, left - $11.80\text{mm}\pm 3.3$) were higher on the right than on the left. The difference in the DJ fos was statistically

significant ($p = 0.004$) while the difference in the WJ fos was not statistically significant ($p = 0.688$). When considering both sides, the mean value of DJ fos was 11.7mm while the mean value of WJ fos was 12.0mm .



Graphic 1: Dimensions of metric parameters of jugular foramen and jugular fossa. AP dia: antero-posterior diameter. ML dia: medio-lateral diameter. DJ fos: depth of jugular fossa. WJ fos: width of jugular fossa

DISCUSSION

The jugular fossa is interestingly complex (Idowu, 2004). This is due to its formation by two different bones namely: the petrous temporal bone and the occipital bone. The complexity is further enhanced by varying nature of structures that traverse the jugular foramen. These structures include the inferior petrosal sinus, glossopharyngeal nerve, vagus nerve, spinal accessory nerve, internal jugular vein, the meningeal branch of the ascending pharyngeal and occipital arteries (Idowu, 2004; Vijisha et al, 2013). The tympanic branch of glossopharyngeal nerve (Jacobson nerve) and the auricular branch of vagus nerve (Arnold nerve) also pass through the canaliculi in the jugular fossa.

Our study focused on the morphology of the jugular foramen which included the shape, presence or absence of septation and presence or absence of a dome. The study also examined the metric parameters which included the antero-posterior diameter (AP dia), the medio-lateral diameter (ML dia), the width of jugular fossa (WJ fos) and the depth of jugular fossa (DJ fos), with the aim of characterizing these parameters and determining their variability both in the same cranium and in different crania in our environment.

One hundred and seventy (170) dry skulls were studied; out of which 77% of the foramens were oval shaped and 23% were round shaped. The oval shaped foramens were more on the right than on the left, while the round shaped foramens were more on

the left than the right. This finding is contrary to a similar work conducted by Sakthivel et al (2014) which reported that the round shaped jugular foramen (58.6%) was more than the oval shaped jugular foramen (41.2%). The shape (and size) of the jugular foramen is determined by the shape (and size) of the internal jugular vein, and this is determined genetically (Khanday et al, 2013).

In a similar manner, the values of AP dia (right - 13.20mm, left - 11.72mm) and ML dia (right - 18.73mm, left - 17.33mm) were higher on the right side than on the left side, and these differences were statistically significant. This right sided dominance observed in the dimensions of the jugular foramen was also reported by several authors (Gupta et al, 2014; Das et al, 2016, Idowu, 2004; Khanday et al, 2013). In a study carried out in Southern Brazil, Pereira et al (2010) did not find any significant difference in the ML dia on either side. However they found significantly higher values of ML dia in male skulls than in female skulls. As for AP dia, they found the values to be significantly higher on the right side than on the left side. Our findings support the commonly held belief that the right jugular foramen is usually larger than the left foramen. Researchers have come to attribute this finding to the fact that the superior sagittal sinus drains into the right transverse sinus (Khandy et al, 2013). However, there exist some variations in the drainage of the superior sagittal sinus, and therefore the real reasons for the right sided dominance are yet to be clearly explained. The difference in the size of internal jugular vein is obvious in the 8 week old fetus, and this is probably determined by the manner of formation of the right and left brachiocephalic veins (Das et al, 2016).

The AP dia of jugular foramen in our study (right - 13.20mm, left - 11.72mm) was higher than the corresponding values reported by Singla et al (2012) (right - 9.32mm, left - 7.34mm), Khandy et al (2013) (right - 1.006cm, left - 0.89cm) and Gupta et al (2014) (right - 11.22mm, left - 9.52mm) which were all conducted in India. It was also higher than the findings of Sakthivel et al (2014) (right - 10.06mm, left - 8.83mm). These differences may be attributed to differences of race.

Furthermore, the values of ML dia in our study (right - 18.73mm, left - 17.33mm) was higher than the values reported by Singla et al (2012) (right - 15.57mm, left - 14.85mm), Khandy et al (2013) (right - 1.46cm, left - 1.39cm) and Gupta et al (2014) (right - 16.5mm, left - 16.02mm). These differences may also be due to racial differences between the two populations.

In our study, the value of DJ fos (right - 12.38mm±2.4, left - 10.95mm±2.8) was higher on the right side than on the left side and this difference was statistically significant. This pattern is similar to the findings of Gupta et al (2014). The values of Dj fos in our work were slightly higher than the values reported by Gupta et al (2014) (right - 11.75mm, left - 11.13) on the right side but not on the left side. The values of WJ fos in our study (right - 12.06mm±3.6, left - 11.80mm±3.3) was slightly higher on the right side than on the left side, but the difference was not significant. The values of WJ fos was higher than that reported by Gupta et al 2014 (right - 6.83mm±1.50, 5.69mm±1.60). These differences may have resulted from difference of race.

Presence of dome over the jugular fossa suggests the presence of a superior jugular bulb (Singla et al, 2012). In our study, presence of dome was found in 67.6% of the skulls (right 27.0% and left 40.6%), while there was absence of dome in 32.4% of the skulls. Das et al (2016) reported that the presence of dome over the jugular fossa on the right and left sides was 96.49% and 86.84% respectively. These values are higher than ours. Their study was conducted in India while our study was conducted in Nigeria and this may be the reason for the difference. Gupta et al (2014) reported that the presence of dome over the jugular fossa in the right and left sides were 74% and 58% respectively. Khanday et al, (2013) reported that there was presence of dome in 20% of the skulls out of which 40% were on the right side and 29% were on the left side. There was absence of dome in 11% of the skulls. Furthermore, Singla et al (2012) reported that presence of dome was found in 66% of skulls bilaterally, in 6% of skulls on the right side only and in 6% of the skulls on the left side only. Dome was absent in 12% of the skulls. These differences yield evidence to

the great variability of the parameters of the jugular fossa.

In the present study, we found absence of septation in 39.4% of the skulls, complete septation in 19.4% (left 11.2% and right 8.2%) and incomplete septation in 41.2% of the skulls. All the septations observed in our study were bipartite. When only the skulls with septations are considered, our study found less complete septation (left - 35.2%, right - 28.6%) than the work of Gupta et al (2014) (left 42%, right 44%). However, more incomplete septations were found in the present study (left - 64.8%, right - 71.4%) than in the work of Gupta et al (2014) (left - 58%, right - 56%). Das et al (2016) reported incomplete septation in 3.5% and 11.4% on the right and left skulls respectively. They also reported that septation was higher in male skulls than in female skulls. Pereira et al (2010) reported absence of septation in 83.8% of skulls in Southern Brazil. Presence of septation reduces the space in the jugular foramen and therefore may increase the pressure and cause compression among the structures traversing the foramen. This may simulate the clinical presentation of glomus jugular tumor and jugular foramen syndrome (Das et al, 2016).

The jugular foramen is very complex due to the variety of structures traversing it. In the present study, oval shaped jugular foramen was more prevalent than round shaped jugular foramen and the presence of septation was more prevalent than its absence. The metric parameters of the jugular foramen showed right side dominance, and the presence of dome was more prevalent than its absence.

Conflict of interest

None

Funding

Self sponsored

Ethical approval

Obtained from the ethics committee of the Faculty of Basic Medical Sciences of our institution.

Informed Consent

Not necessary

Contributions

UUU: Concepts, Design, intellectual content, data analysis, manuscript editing, manuscript review. CMO: Design, intellectual content, literature search, data analysis, manuscript preparation, manuscript editing. CU: Concept, design, intellectual content, statistical analysis, manuscript editing, manuscript review. IFO: Design, intellectual content, literature search, data acquisition, data analysis, manuscript preparation. HCN: Concept, Design, intellectual content, literature search, data acquisition, data analysis. JE: Design, intellectual content, data analysis, manuscript preparation, manuscript editing

REFERENCES

- Das SS, Saluja S, Vasudeva N. 2016. Complete morphometric analysis of jugular foramen and its clinical implications. *J Craniovertebr Junction Spine*. 7: 257–64.
- Gupta C, Kurian P, Seva PN, Kalthur SG, D'souza AS. 2014. A morphological and morphometric study of jugular foramen in dry skulls with its clinical implications. *J Craniovertebr Junction Spine*. 5: 118–21.
- Idowu OE. 2004. The jugular foramen — a morphometric study. *Folia Morphol*. 63: 419–22
- Khanday S, Subramanian RK, Rajendran M, Hassan AU, Khan SH. 2013. Morphological and morphometric study of jugular foramen in South Indian population. *Int J Anat Res* 1: 122-27.
- Kumar A, Ritu, AkhtarMJ, Kumar A. 2015. Variations in jugular foramen of human skull. <http://nepjol.info/index.php/AJMS> (accessed September 2018)
- Linn J, Peters F, Moriggl B, Naidich TP, Brückmann H, Yousry I. 2009. The jugular foramen: Imaging strategy and detailed anatomy at 3T. *AJNR Am J Neuroradiol*. 30: 34–41
- Pereira GA, Lopes PT, Santos AM. 2010. Morphometric aspects of the jugular foramen in dry skulls of adult individuals in Southern Brazil. *J Morphol Sci*. 27: 3–5
- Ramina R, Maniglia JJ, Fernandes YB, Paschoal JR, Pfeilsticker LN, Neto MC, Borges G. 2004. Jugular foramen tumors: Diagnosis and treatment. URL: <https://www.ncbi.nlm.nih.gov/pubmed/15329020> (accessed September 2018).
- Sakthivel KM, Balaji TK, Moni AS, Narayanan G, Kumar KS. 2014. Study of Jugular Foramen – A Case Report. *Journal of Dental and Medical Sciences*. 13: 63-67.

- Singla A, Sahni D, Aggarwal A, Gupta T, Kaur H. 2012. Morphometric study of the Jugular foramen in Northwest Indian population. *J Postgrad Med Edu Res.* 46: 165-71
- Standring S (ed). 2008. *Gray's Anatomy, the anatomical basis of clinical practice.* 40th Ed. Londres. Churchill Livingstone Elsevier. p 415.
- Vijisha P, Bilodi AK, Lokeshmaran. 2013. Morphometric study of jugular foramen in Tamil Nadu region. *Natl J Clin Anat.* 2: 71–74.
- Vlajkovic S, Vasovic L, Dakovic-Bjelakovic M, Stankovic S, Popovic J, Cukuranovic R. 2010. Human bony jugular foramen: Some additional morphological and morphometric features. *Med SciMonit.* 16: BR140–46.