



Metástasis cerebrales en un paciente con antecedente de mixoma cardíaco: reporte de caso y revisión de la literatura

Brain metastases in a patient with antecedent of cardiac myxoma: a Case Report and Review of Literature

Metástases cerebrais em paciente com antecedente de mixoma cardíaco: relato de caso e revisão de literatura



Raymundo Solís-Gómez^{1,2}, Natalia Dávalos-Cabral^{1,3},
Gerardo Arrieta-Limón^{1,4}, Brandon A. Hurtado-Presa^{1,5},
Andrea Salgado-Alvear^{1,6}, Laura M. Reyes-Martínez^{1,7},
Fabiola E. Serrano-Arias^{1,8}

DATOS DE AUTORES

1. Dirección de enseñanza, Instituto Nacional de Neurología y Neurocirugía Manuel Velasco Suárez (Ciudad de México, México).
2. E-mail de contacto: ray.sogo99@gmail.com ORCID: <https://orcid.org/0000-0003-4185-8655>
3. ORCID: <https://orcid.org/0009-0001-6340-5123>
4. ORCID: <https://orcid.org/0009-0008-3056-4807>
5. ORCID: <https://orcid.org/0009-0008-4929-0439>
6. ORCID: <https://orcid.org/0000-0002-0232-2578>
7. ORCID: <https://orcid.org/0009-0007-8821-0377>
8. Clínica de enfermedad vascular cerebral, Instituto Nacional de Neurología y Neurocirugía Manuel Velasco Suárez (Ciudad de México, México). ORCID: <https://orcid.org/0000-0002-0350-3477>

Recibido: 2024-04-05 Aceptado: 2024-08-27

doi DOI: <http://dx.doi.org/10.31053/1853.0605.v81.n4.44662>



<https://creativecommons.org/licenses/by-nc/4.0/>

©Universidad Nacional de Córdoba



Metástasis cerebrales en un paciente con antecedente de mixoma cardíaco: reporte de caso y revisión de la literatura

CONCEPTOS CLAVE.

¿Qué se sabe sobre el tema?

Los mixomas son una neoplasia cardíaca infrecuente; pueden provocar embolismos por desprendimiento de un fragmento tumoral, lo que puede ocasionar desarrollo de metástasis después de años en el sitio de implantación de la porción tumoral desprendida.

¿Qué aporta este trabajo?

Existen pocos casos descritos de metástasis cerebrales secundarios a mixoma cardíaco, posterior al diagnóstico y resección de la masa tumoral, este reporte de caso podría contribuir en la discusión de esta rara presentación, en una enfermedad de baja frecuencia.

Divulgación

Los mixomas son una neoplasia del corazón rara que puede ocasionar complicaciones como infartos cerebrales y metástasis a lo largo del tiempo. Estos infartos son ocasionados cuando un fragmento del tumor se desprende y pasa a circulación sanguínea, a través de la que ocluye vasos sanguíneos cerebrales. El tratamiento con cirugía cura la enfermedad por el mixoma, sin embargo, no previene el riesgo de metástasis cerebrales a largo plazo.



Metástasis cerebrales en un paciente con antecedente de mixoma cardíaco: reporte de caso y revisión de la literatura

Resumen

Palabras clave:

neoplasias
encefálicas;
metástasis de la
neoplasia; neoplasias
cardíacas; mixoma;
accidente
cerebrovascular
embólico

Introducción. Los mixomas cardíacos son las neoplasias benignas más comunes del corazón, principalmente ubicadas en el atrio izquierdo. El tratamiento preferido es la resección del mixoma. Este método no solo previene complicaciones, sino que también tiene una baja tasa de recurrencia. Las metástasis cerebrales suelen ocurrir cuando fragmentos tumorales embolizan e implantan en el lugar de destino. **Presentación del caso.** Informamos el caso de un paciente con múltiples metástasis cerebrales, encontradas durante el seguimiento, después de presentar un accidente cerebrovascular. Este caso destaca porque la embolización causante de la metástasis cerebral podría haber ocurrido tanto durante el accidente cerebrovascular isquémico como durante la remoción del mixoma cardíaco. En nuestro caso, el paciente fue evaluado durante el seguimiento con resonancia magnética cerebral, encontrando múltiples lesiones metastásicas. Para determinar el tipo de lesión, se realizó una biopsia y el diagnóstico histológico indicativo de tejido metastásico de mixoma atrial izquierdo. **Conclusión.** Los pacientes con cardioembolismo deben someterse a un protocolo diagnóstico completo para distinguir la causa de la embolia, ya sea un coágulo sanguíneo o un émbolo tumoral. El tratamiento de elección es la resección del mixoma, que cura los síntomas neurológicos primarios y previene complicaciones neurológicas. Sin embargo, es esencial mantener una vigilancia activa por más tiempo para la detección y tratamiento adecuado de metástasis cerebrales.



Brain metastases in a patient with antecedent of cardiac myxoma: a case report and review of literature

Abstract

Keywords:

brain neoplasms;
neoplasm
metastasis; heart
neoplasms;
myxoma;
embolic stroke

Introduction. Cardiac myxomas are the most common benign neoplasms of the heart, mainly located in the left atrium. The preferred treatment is the resection of the myxoma. This method not only prevents complications but also has a low recurrence rate. Brain metastases usually occur when tumor fragments embolize and implant at the destination place. **Case presentation.** We report the case of a patient with multiple brain metastases, found during follow-up, after the presentation of stroke. This case stands out because the embolization causing the brain metastasis might have occurred either during the ischemic stroke or when the cardiac myxoma was being removed. In our case, the patient was evaluated during follow-up with brain magnetic resonance imaging, finding multiple metastatic lesions. To determine the type of lesion, a biopsy was performed and the histological diagnosis, which was indicative of metastatic tissue of left atrial myxoma. **Conclusion.** Patients with cardioembolism should undergo a complete diagnostic protocol to distinguish the cause of embolization, whether it is a blood clot or a tumor embolus. The treatment of choice is the resection of the myxoma, which cures the primary neurological symptoms and prevents neurological complications. However, it is essential to maintain active surveillance for a longer time for the detection and appropriate treatment of brain metastases.



Metástases cerebrais em paciente com antecedente de mixoma cardíaco: relato de caso e revisão de literatura

Resumo

Palavras-chave:

neoplasias
encefálicas;
metástase
tumoral;
neoplasias
cardíacas;
mixoma; AVC
embólico

Introdução. Mixomas cardíacos são as neoplasias benignas mais comuns do coração, principalmente localizadas no átrio esquerdo. O tratamento preferido é a ressecção do mixoma. Este método não apenas previne complicações, mas também tem baixa taxa de recorrência. Metástases cerebrais geralmente ocorrem quando fragmentos tumorais embolizam e se implantam no local de destino. Apresentação do caso. Relatamos o caso de um paciente com múltiplas metástases cerebrais, encontradas durante o acompanhamento, após apresentar um derrame. Este caso se destaca porque a embolização causando a metástase cerebral pode ter ocorrido tanto durante o derrame isquêmico quanto durante a remoção do mixoma cardíaco. Em nosso caso, o paciente foi avaliado durante o acompanhamento com ressonância magnética cerebral, encontrando múltiplas lesões metastáticas. Para determinar o tipo de lesão, foi realizada uma biópsia e o diagnóstico histológico indicativo de tecido metastático de mixoma atrial esquerdo. Conclusão. Pacientes com cardioembolismo devem passar por um protocolo diagnóstico completo para distinguir a causa da embolia, seja um coágulo sanguíneo ou um êmbolo tumoral. O tratamento de escolha é a ressecção do mixoma, que cura os sintomas neurológicos primários e previne complicações neurológicas. No entanto, é essencial manter uma vigilância ativa por mais tempo para a detecção e tratamento adequado de metástases cerebrais.



Introduction

Myxomas are the most frequent neoplasms of the heart. 75% of them arise from the left atrium, the most common place of origin. They develop in adults, at ages between the third and sixth decades of life, more frequently in women ⁽¹⁾. They usually have favorable outcomes, with a 20-year survival of 85%, and a recurrence rate of less than 5% ^(2,3). Complete surgery of the myxoma is the treatment of choice to cure the disease and prevent neurological complications, however, incomplete resection of the tumor can result in multifocal tumors and embolism as recurrence of the disease. The embolization of tumor fragments occurs in about 45% of patients ⁽⁴⁾. The most frequent site of embolization is the central nervous system (CNS), leading to neurological manifestations in the form of stroke, cerebral hemorrhage due to aneurysm formation or cerebral metastasis due to metastatic deposits of myxoma ⁽³⁾.

Myxomas are benign neoplasms and slow proliferation lesions. Tumor emboli can remain in any vascular bed and tumor cells can maintain their viability, forming distant metastases. There have been very few reported cases of cerebral metastasis, found from 3 months to years after the diagnosis of myxoma ⁽⁵⁾. We present the rare case of a patient with left atrial myxoma with multiple metastatic lesions in the CNS to highlight the importance of active surveillance for the detection of metastatic lesions and recurrence of the disease to provide appropriate treatment.

Case presentation

A 54-year-old woman with no significant medical history. Five months before her admission, she experienced transient symptoms of dizziness and decreased strength in her right hand. She went to the emergency room due to a sudden onset of generalized seizures. The magnetic resonance imaging showed no lesions (**figure 1A**). She was protocolized for the history of transient ischemic attack. The carotid ultrasound showed no atherosclerotic disease. The transthoracic echocardiogram revealed an intracardiac mass measuring 5.6 x 2.8 cm in size and a volume of 10 cc, attached to the interatrial septum by a pedicle, mobile, and protruding into the left ventricle through the anterior mitral valve.

A month later, resection of the intracardiac tumor was performed with placement of a mitral valve prosthesis and closure of the patent foramen ovale. The histopathological diagnosis reported a benign neoplasm of mesenchymal lineage with fusiform and stellar cells grouped together and forming pseudovascular channels immersed in a mucopolysaccharide-rich matrix, compatible with myxoma.

Three months into follow-up, the patient presented with visual field disturbances with left homonymous hemianopia, seeking evaluation several days after the onset of symptoms. The simple skull tomography showed a right occipital hypodensity (**figure 1B**) considered cerebral ischemia, discharged with medical treatment.

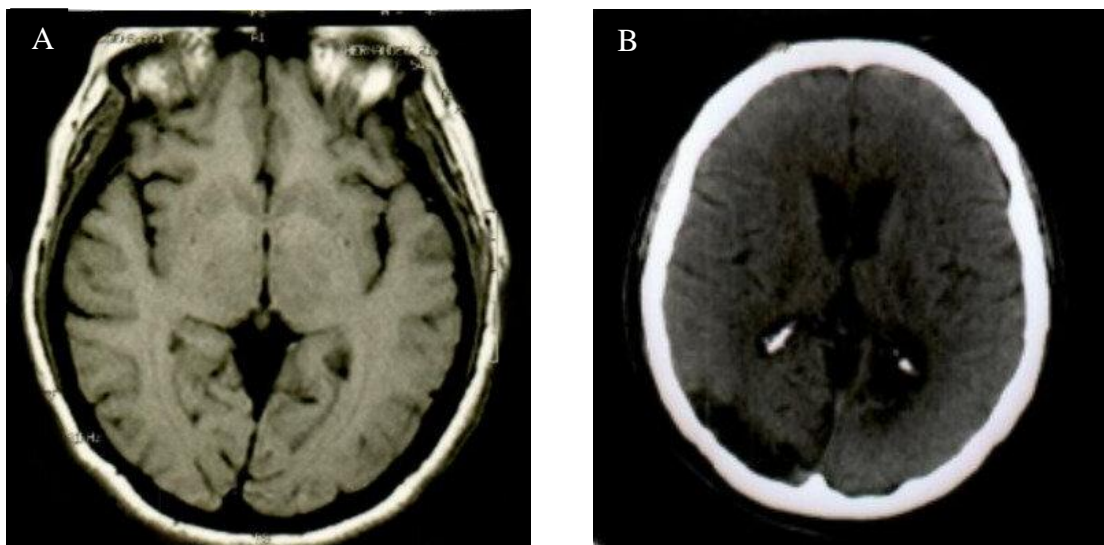


Figure 1. (A) Magnetic resonance imaging without evidence of lesions in the initial assessment.
(B) Computerized tomography of the skull with right occipital lesion.

The patient discontinued follow-up, returning three years later due to generalized seizures. During this hospitalization, brain imaging reported lesions suggestive of brain metastases in different locations, including the site of the right

occipital infarction (figure 2AB). The histopathological analysis of the brain biopsy identified neoplastic mesenchymal tissue related to myxoma, with evidence of old hemorrhage and abundant congestive vessels.

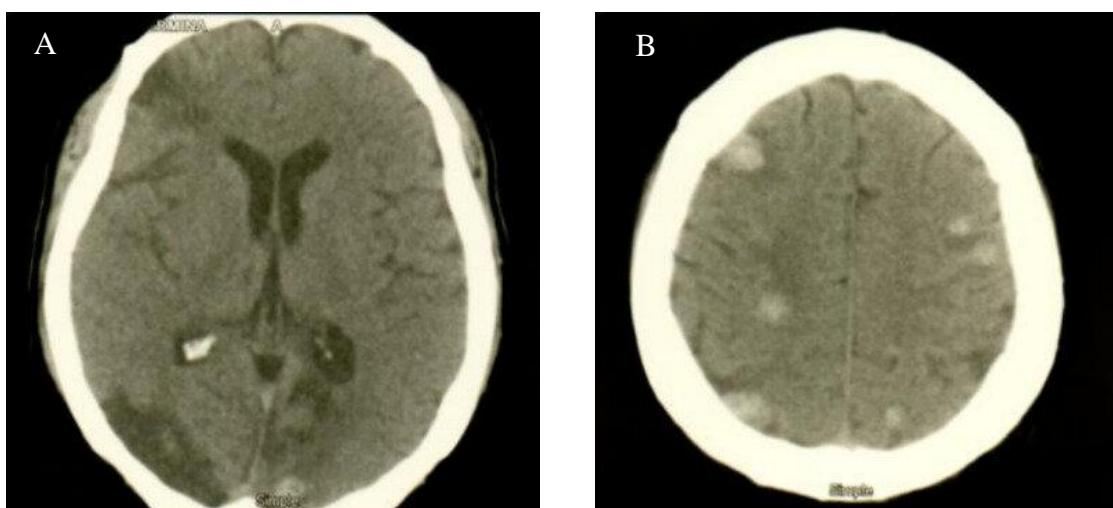


Figure 2AB. Computerized tomography of the skull showing metastatic lesions involving multiple territories.



Discussion

Myxomas are the most common benign cardiac tumors, most of them are sporadic and have slow proliferation. They are thought to derive from multipotential mesenchymal cells of the endocardium⁽⁶⁾.

Embolism phenomena in patients with myxomas occur in 22.4% to 45% of cases, with cerebral embolization in half of the patients who present it^(7,8). Factors associated with a higher risk of embolism include the external villous appearance, NYHA class (I/II), hypertension, irregular tumor surface, atypical location, narrow base, and elevated fibrinogen concentrations^(7,9). The risk of embolism has also been attributed to blood flow turbulence and the timing of surgical treatment due to tumor detachment^(8,10).

Embolization is due to the detachment of a tumor fragment from the cardiac myxoma towards the systemic circulation, and the site of the embolus can be related to the location of the tumor. Right myxomas can cause pulmonary embolisms, and left ones can cause systemic embolisms that involve the brain, coronary arteries, or eyes⁽¹⁰⁾, in addition to being more frequent embolization of left atrial myxomas⁽⁸⁾. Interestingly, at the time of starting the patient's diagnostic protocol, it was detected that the stroke had a cardioembolic origin. It is thought that cerebral embolization occurs towards some vessels of the CNS⁽¹³⁾, resulting in cerebral ischemia, infarction, and in some cases, aneurysm formation⁽⁵⁾.

The manifestations of cerebral embolization are three: ischemic stroke, aneurysms, and cerebral metastases^(3,5,10). Ischemic stroke are mainly due to tumor embolism, causing occlusion of the cerebral vessels; aneurysms occur due to infiltration of the cerebral vessels by myxomatous cells through the vasa vasorum, with destruction of their architecture, weakening of the subintimal tissue, in addition to producing perivascular injury with subsequent scarring and formation of pseudoaneurysms⁽¹⁰⁾. Metastases occur due to a transgression of the vessel wall, with focal alteration of the internal elastic lamina, creating a nest for cerebral hemorrhage, with the consequent seeding and growth of the tumor tissue in the cerebral parenchyma^(4,11).

In addition to the higher risk of metastasis, related to overproduction of components involved in myxoma growth, such as CXC or

chemotactic chemokines, endothelin 1 (ET-1), interleukin 8, and growth-related oncogene- α ^(8,10).

The spectrum of CNS manifestations is broad and includes progressive headache, nausea, vomiting due to increased intracranial pressure, weakness or numbness of limbs or body, onset of new seizures, most of them due to hemorrhage due to aneurysm formation or metastatic space or occupying lesions⁽⁵⁾. In the case presented, loss of control of urinary sphincters, depressive symptoms, and behavioral alterations were found in the clinical spectrum when metastatic lesions were found.

Today there is no standard therapy for CNS complications related to myxoma, resection surgery of the myxoma is the treatment of choice to prevent additional embolization and neurological complications⁽⁴⁾, in addition to having a good prognosis⁽⁵⁾, however, it does not prevent the risk of cerebral metastases⁽⁸⁾, which are presented at the same time as the myxoma, months or even years after the initial finding of the cardiac tumor^(4,6) or otherwise, before the detection of the cardiac tumor; in this case, metastatic lesions were detected three years after the cardiac mass was diagnosed and treated.

A craniotomy is usually performed to resect metastatic lesions, as in the case we presented. However, successful cases have been described with lesion remission using gamma knife radiosurgery and temozolomide⁽³⁾, the use of chemotherapy with doxorubicin and ifosfamide, with or without radiotherapy to eliminate proliferating myxomatous cells, could also have adequate results in case of multiple cerebral metastases to obtain a longer time without recurrences^(6,12).

The prognosis of myxoma surgical treatment is generally good, as presented in this case, with almost no postoperative complications. However, due to the risk of metastasis and recurrence of the disease, annual follow-up is recommended, at least for more than 3 years and could even be considered up to eight years later, with the performance of cerebral magnetic resonance due to the risk of late metastasis⁽¹¹⁾.



Conclusion

Patients with a cardioembolic event should undergo a complete diagnostic protocol to distinguish the cause of embolization between a blood clot or a tumor embolus. This is due to the ability of the myxoma to spread to the brain, which can result in the development of CNS metastases and the recurrence of long-term cerebral infarctions.

References

1. Saad EA, Mukherjee T, Gandour G, Fatayerji N, Rammal A, Samuel P, Abdallah N, Ashok T. Cardiac myxomas: causes, presentations, diagnosis, and management. *Ir J Med Sci.* 2024 Apr;193(2):677-688. doi: 10.1007/s11845-023-03531-2.
2. Griborio-Guzman AG, Aseyev OI, Shah H, Sadreddini M. Cardiac myxomas: clinical presentation, diagnosis and management. *Heart.* 2022 May 12;108(11):827-833. doi: 10.1136/heartjnl-2021-319479.
3. Ma K, Zhao D, Li X, Duan H, Yan C, Wang S, Zeng L, Xu K, Lai Y, Chen B, Mu N, Yang C, Quan Y, Li Z, Wang X, Feng H, Li F. Case report: Multiple brain metastases of atrial myxoma: Clinical experience and literature review. *Front Neurol.* 2023 Feb 8;13:1046441. doi: 10.3389/fneur.2022.1046441.
4. Rajeshwari M, Subramanian P, Suri V, Nambirajan A, Garg A, Vibha D, Phalak M, Sharma MC. Metastatic lesions of atrial myxoma. A pathologist can clinch them all. *Neuropathology.* 2020 Jun;40(3):295-301. doi: 10.1111/neup.12640.
5. Rodrigues D, Matthews N, Scoones D, Aziz F, Nath F. Recurrent cerebral metastasis from a cardiac myxoma: case report and review of literature. *Br J Neurosurg.* 2006 Oct;20(5):318-20. doi: 10.1080/02688690601000394.
6. Wan Y, Du H, Zhang L, Guo S, Xu L, Li Y, He H, Zhou L, Chen Y, Mao L, Jin H, Hu B. Multiple cerebral metastases and metastatic aneurysms in patients with left atrial Myxoma: a case report. *BMC Neurol.* 2019 Oct 23;19(1):249. doi: 10.1186/s12883-019-1474-4.
7. Liu Y, Wang J, Guo L, Ping L. Risk factors of embolism for the cardiac myxoma patients: a systematic review and metanalysis. *BMC Cardiovasc Disord.* 2020 Jul 25;20(1):348. doi: 10.1186/s12872-020-01631-w.
8. Rose D, Papa A, Tomao S, Greco E, Zacharias J. Cerebral Metastases in Patients with Left Atrial Myxoma. *J Card Surg.* 2016 May;31(5):289-93. doi: 10.1111/jocs.12727.
9. Amemiya K, Yonemoto Y, Ishibashi-Ueda H, Matsumoto M, Ohta-Ogo K, Ikeda Y, Kobayashi J, Fukushima S, Fujita T, Hatakeyama K. Morphological characteristics of cardiac myxoma causing embolism: a series of 40 years of experience at a single institute. *Virchows Arch.* 2023 Feb;482(2):377-384. doi: 10.1007/s00428-022-03461-x.
10. Niño AO, Ramirez LAC, Leal JCA, Ortiz SM, Cordoba LG. Brain manifestations secondary to auricular myxoma. *Radiol Case Rep.* 2020 Sep 17;15(11):2371-2374. doi: 10.1016/j.radcr.2020.08.043.
11. Ghodasara SA, Balasubramanian R, Varadharajan S, Shobhanaa PS. Cardiac phoenix in the brain-occult intracranial hemorrhagic metastases from completely resected atrial myxoma. *Surg Neurol Int.* 2020 Nov 11;11:383. doi: 10.25259/SNI_410_2020.
12. Bernet F, Stulz PM, Carrel TP. Long-term remission after resection, chemotherapy, and irradiation of a metastatic myxoma. *Ann Thorac Surg.* 1998 Nov;66(5):1791-2. doi: 10.1016/s0003-4975(98)00917-5.

**Conflicto de interés:**

Ninguno.

Limitaciones de responsabilidad

La responsabilidad de esta publicación es de los autores.

Fuentes de apoyo

La presente investigación no contó con fuentes de apoyo.

Originalidad

Este artículo es original y no ha sido enviado para su publicación a otro medio de difusión científica en forma completa ni parcialmente.

Cesión de derechos

Quienes participaron en la elaboración de este artículo, ceden los derechos de autor a la Universidad Nacional de Córdoba para publicar en la Revista de la Facultad de Ciencias Médicas de Córdoba y realizar las traducciones necesarias al idioma inglés.

Contribución de los autores

Quienes participaron en la elaboración de este artículo, han trabajado en la concepción del diseño, recolección de la información y elaboración del manuscrito, haciéndose públicamente responsables de su contenido y aprobando su versión final.